

**PATIENT**

Tang Abramowitz

PRESENTING CLINICAL SIGNS

Patient presented for acute vomiting and bloody diarrhea that started this morning, tried to eat breakfast and then threw everything up. Also sneezing with thick discharge, owner states was at a boarding facility this past weekend

SPECIES

Canine

Abnormal PE/Chem/CBC/UA Results: Leukocytosis with a primary neutrophilia

BREED

French Bulldog

RADIOGRAPHIC STUDY OF THE THORAX & ABDOMEN

Right/left lateral and ventrodorsal views of the thorax and abdomen totaling 5 images available for review.

RADIOGRAPHIC FINDINGS**Thorax**

Serial vertebral malformation is seen in the cranial and mid thoracic spine at T3 through T8 with mild spinal kyphosis.

The degree of pulmonary inflation is fair. A mild bronchial lung pattern with mild peribronchial cuffing is seen accentuating the caudodorsal lung.

There is no evidence of cardiovascular changes. The vertebral heart score is inaccurate owing to the vertebral malformation; however, no overall enlargement and no specific chamber enlargement are recognized. The pulmonary vasculature is thin.

The width of the trachea is considered within breed related normal limits.

Abdomen

Early lumbosacral spondylosis is present.

The radiographic presentation of the kidneys is within normal limits.

The overall size of the liver is rather small.

There is mild gastric aerophagia.

The small intestinal loops are non-dilated, and evenly distributed throughout the mid abdomen. No radiopaque foreign material is seen. There is no evidence of intestinal plication.

The colon appears to be empty.

RADIOGRAPHIC DIAGNOSIS

- Mild active bronchial lung pattern.
- Radiographically normal abdomen with largely empty gastrointestinal tract.
- Mild microhepatica.
- Congenital vertebral malformation.

SEX

MN

AGE

3 Years

INTERPRETED BY

Nele Eley, DVM
Dr. med. Vet. DipECVDI

HOSPITAL NAME

Boca Park Animal
Hospital

REFERRING VET

Dr. Corinna Gorgon

INVOICE

47376

DATE

9-12-21



PATIENT

Tang Abramowitz

INTERPRETATION OF THE FINDINGS & FURTHER RECOMMENDATIONS

SPECIES

Canine

The radiographic findings of the thorax suggest potential for mild active lower airway disease. The degree of changes does not necessarily correlate with the clinical signs as radiographic changes may lag behind. Infectious tracheobronchitis or other infectious bronchitis such as viral, bacterial, parasitic, or protozoal appear to be a potential. Eosinophilic / allergic bronchopneumopathy is a possible differential diagnosis as well.

BREED

French Bulldog

The small size of the liver may be incidental and a normal anatomic variant. Portosystemic shunting and fibrosis are less likely but possible differential diagnoses.

SEX

MN

There is no evidence of mechanical ileus at the time of the radiographic study. Should the clinical signs have continued, abdominal ultrasound would be an ideal option for further definition in this patient in the context of the gastrointestinal signs.

Lower airway endoscopy with airway sampling could be considered to further define the radiographic changes; however, this rather invasive procedure may be discussed versus a trial of empirical management for bronchitis.

AGE

3 Years

INTERPRETED BY

Nele Eley, DVM
Dr. med. Vet. DipECVDI

HOSPITAL NAME

Boca Park Animal
Hospital

REFERRING VET

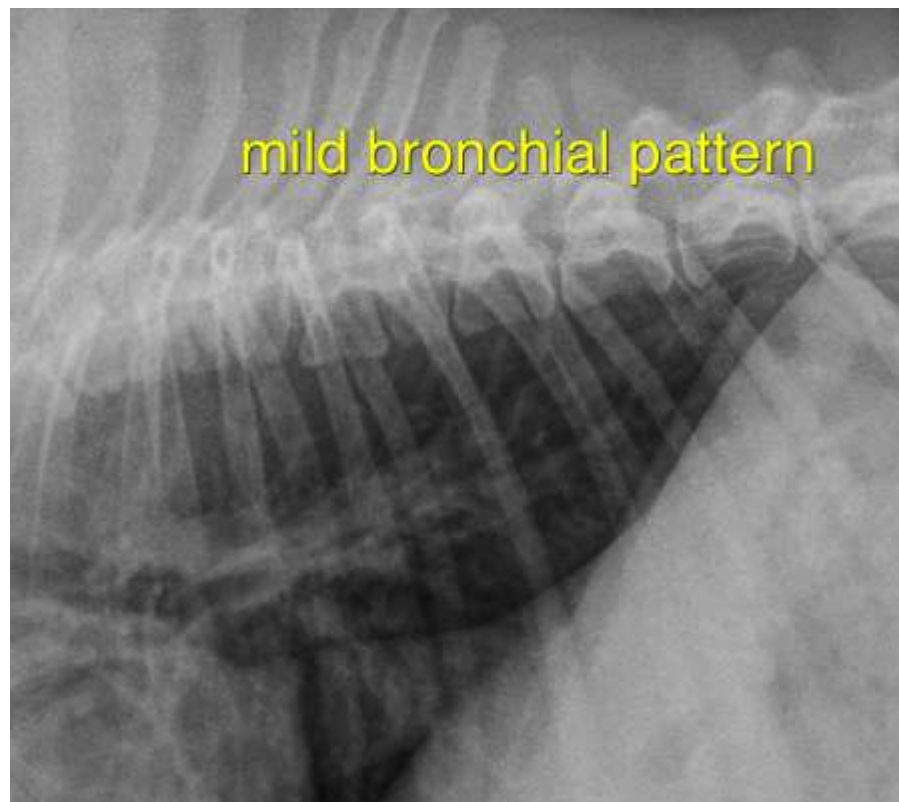
Dr. Corinna Gorgon

INVOICE

47376

DATE

9-12-21





PATIENT

Tang Abramowitz

The information and recommendations provided are based on the images presented by the referring veterinarian. No evaluation can be communicated regarding pathology that was not visible in the image/video clips provided.

SPECIES

Canine

Thank you for this referral. If the clinical or image interpretation does not parallel your findings or if I can be of any further assistance please contact me.

BREED

French Bulldog

Nele Eley, DVM, Dr. med. vet., DipECVDI
European Specialist in Veterinary Diagnostic Imaging, Cert. Radiology,
Senior lecturer University of Giessen, Germany, Veterinary Faculty, Department of Radiology
Nele.Eley@sonopath.com

SEX

MN

AGE

3 Years

INTERPRETED BY

Nele Eley, DVM
Dr. med. Vet. DipECVDI

HOSPITAL NAME

Boca Park Animal
Hospital

REFERRING VET

Dr. Corinna Gorgon

INVOICE

47376

DATE

9-12-21