

**PATIENT**

Oliver Tognoli

**PRESENTING CLINICAL SIGNS**

Chronic sneezing, history of feline herpes per O. Sneezing has become worse recently with yellow-blood tinged mucous discharge, and has started coughing as well. P is indoor/outdoor and an avid hunter.

**SPECIES**

Feline

Abnormal PE/Chem/CBC/UA Results: Mildly increased respiratory effort with bilateral wheeze auscultated. Mild serous ocular discharge.

**RADIOGRAPHIC STUDY OF THE THORAX****BREED**

DSH

Right/left lateral and ventrodorsal views totaling 3 images available for review.

**SEX**

MN

**RADIOGRAPHIC FINDINGS**

The chest is expanded. The lungs are deeply inflated with wide lumbodiaphragmatic angles and flat diaphragmatic cupola. There is a moderate generalized bronchial lung pattern with marked peribronchial cuffing.

The cardiac silhouette is upright and thin. The pulmonary vasculature is thin as well.

**AGE**

9 Years

Course and width of the trachea are considered within normal limits.

There is no evidence of pathologic mediastinal widening.

The osseous structures present within age related normal limits.

The stomach is post prandial. Moderate gastric aerophagia is seen.

**INTERPRETED BY**

Nele Eley, DVM  
Dr. med. Vet. DipECVDI

**RADIOGRAPHIC DIAGNOSIS**

- Chronic active lower airway pattern.
- Aerophagia.
- Hypovolemia with mild microcardia and underperfusion of the lung.

**HOSPITAL NAME**

Cornelius Veterinary  
Clinic

**INTERPRETATION OF THE FINDINGS & FURTHER RECOMMENDATIONS**

The radiographic study reveals evidence of chronic active lower airway disease with mild air trapping. Underlying allergic lower airway syndrome is considered likely however superinfection in terms of either viral, bacterial, and less likely parasitic or protozoal bronchitis appears to be a potential in this patient synthesizing the radiographic findings with the clinical history. Consider a clinical trial of treatment for bronchitis along with antiallergic treatment versus immediate further definition by means of upper and lower airway sampling.

**REFERRING VET**

Angela Vinton

**INVOICE**

47374

**DATE**

9-11-21



**PATIENT**

Oliver Tognoli

**SPECIES**

Feline

**BREED**

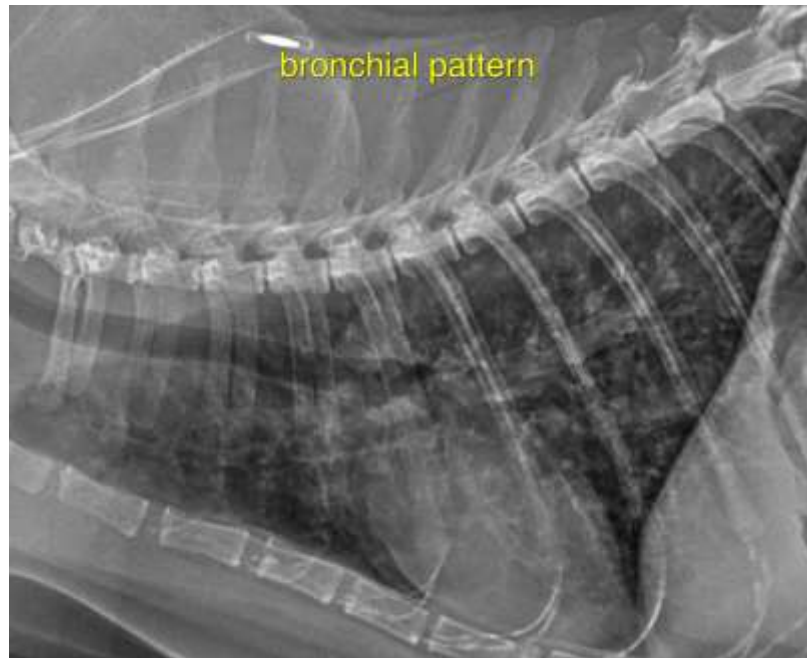
DSH

**SEX**

MN

**AGE**

9 Years



**INTERPRETED BY**

Nele Eley, DVM  
Dr. med. Vet. DipECVDI

The information and recommendations provided are based on the images presented by the referring veterinarian. No evaluation can be communicated regarding pathology that was not visible in the image/video clips provided.

Thank you for this referral. If the clinical or image interpretation does not parallel your findings or if I can be of any further assistance please contact me.

**HOSPITAL NAME**

Cornelius Veterinary  
Clinic

**Nele Eley**, DVM, Dr. med. vet., DipECVDI  
European Specialist in Veterinary Diagnostic Imaging, Cert. Radiology,  
Senior lecturer University of Giessen, Germany, Veterinary Faculty, Department of Radiology  
Nele.Eley@sonopath.com

**REFERRING VET**

Angela Vinton

**INVOICE**

47374

**DATE**

9-11-21