

**PATIENT**

Lily Avery

**PRESENTING CLINICAL SIGNS**

chronic vomiting, changed food a few times with no improvement  
Abnormal PE/Chem/CBC/UA Results: increased WBCs, severe pancreatitis, mild hyperglycemia

**SPECIES**

Feline

**RADIOGRAPHIC STUDY OF THE ABDOMEN**

Right/left lateral and ventrodorsal whole body views totaling 3 images available for review.

**BREED**

Domestic Shorthair

Abdominal read requested.

**RADIOGRAPHIC FINDINGS**

Mild T11/12 spondylosis is seen. There is mild bilateral coxofemoral osteoarthritis.

**SEX**

Female Spayed

No abnormalities of the extraabdominal soft tissues are noted. The abdominal wall is smooth and thin.

The serosal detail is maintained throughout the peritoneal and retroperitoneal space.

**AGE**

13 Years

The liver is appropriate in position, size and presents uniform opacity.

The splenic head is in the anticipated position and within normal limits for size and opacity. The splenic tail is not seen.

**INTERPRETED BY**Nele Eley, DVM  
Dr. med. Vet. DipECVDI

Both kidneys are seen and present with normal size, shape, delineation and opacity. The urinary bladder is in its anticipated position. No radiopaque calculi are noted throughout the upper and lower urinary tract.

**HOSPITAL NAME**St. Catharine's Animal  
Hospital

The stomach is post-prandial with no evidence of abnormal position or content. The position of the stomach is within normal limits.

Mild even dilation of the small intestine is seen with a mix of an elementary and gas pattern.

A moderate amount of fecal material and gas is present within the colon.

**REFERRING VET**

Dr. Masoud

**RADIOGRAPHIC DIAGNOSIS**

- Small intestinal maldigestion pattern.

**INVOICE**

47371

**INTERPRETATION OF THE FINDINGS & FURTHER RECOMMENDATIONS**

The radiographic study reveals a small intestinal maldigestion pattern with radiographic evidence of functional / paralytic ileus which correlates with the history of pancreatitis. Other causes of functional ileus including enteropathy and metabolic disease cannot be ruled out entirely. Correlate with the laboratory and ultrasonographic findings as available.

**DATE**

9-11-21



**PATIENT**

Lily Avery

**SPECIES**

Feline

**BREED**

Domestic Shorthair

**SEX**

Female Spayed

**AGE**

13 Years

**INTERPRETED BY**

Nele Eley, DVM  
Dr. med. Vet. DipECVDI

**HOSPITAL NAME**

St. Catharine's Animal  
Hospital

**REFERRING VET**

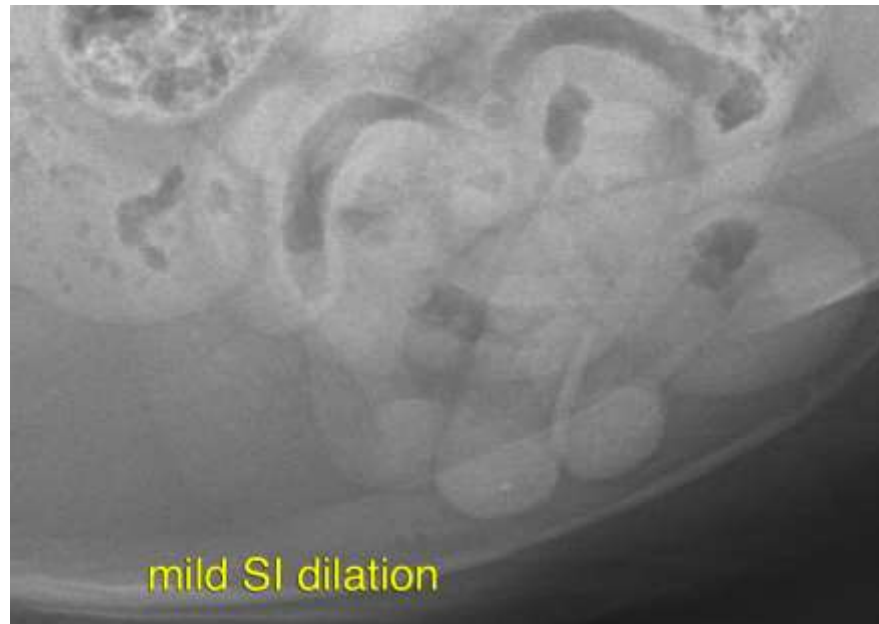
Dr. Masoud

**INVOICE**

47371

**DATE**

9-11-21



The information and recommendations provided are based on the images presented by the referring veterinarian. No evaluation can be communicated regarding pathology that was not visible in the image/video clips provided.

Thank you for this referral. If the clinical or image interpretation does not parallel your findings or if I can be of any further assistance please contact me.

**Nele Eley**, DVM, Dr. med. vet., DipECVDI  
European Specialist in Veterinary Diagnostic Imaging, Cert. Radiology,  
Senior lecturer University of Giessen, Germany, Veterinary Faculty, Department of Radiology  
Nele.Eley@sonopath.com