



PATIENT PRESENTING CLINICAL SIGNS

Marvin Boyer

Owner reports that Marvin has recently started having coughing episodes. He has done is about 4 times now, the first episode being on Aug 29th. His respiration rate after the coughing episodes is also elevated (around 42 bpm at the highest). His resting RR prior to this in May was around 22 bpm. No v/d/c/s. E/D well. On RC early renal support as previously diagnosed with persistently elevated SDMA and suspected early CKD. On atenolol 6.25 mg PO BID as well as daily omega 3s as previously diagnosed by echo (May 2022) with left ventricular hyperplasia, mitral valve dysplasia, and suspected early onset HCM. He also has a history of seasonal environmental allergies and was well managed on Atopica. She has been tapering him off slowly the Atopica, and she thinks the cough started around the same time she was decreasing his Atopica dose.

Abnormal PE/Chem/CBC/UA Results: Grade 4/6 systolic heart murmur with gallop. Mildly overweight at BCS 3.5/5. Otherwise appears healthy on PE. Could not elicit a cough on tracheal palpation. Did swallow a few times excessively when I palpated his throat region. Bloodwork performed today: Unremarkable chemistry, SDMA, and CBC other than mildly elevated GGT. Thoracic radiographs performed for your evaluation today. Ddx: Feline allergic bronchitis (asthma) is top differential, but other ddx includes CHF/heart enlargement as cause of cough, or infectious

SPECIES

Feline

BREED

Siamese

SEX

MN

AGE

3 Years

RADIOGRAPHIC STUDY OF THE THORAX

Right/left lateral and ventrodorsal views totaling 3 images available for review.

RADIOGRAPHIC FINDINGS

The degree of pulmonary inflation is deep. The ribcage is expanded. The lumbodiaphragmatic angles are wide. Mild flattening of the diaphragmatic cupola is seen.

There is moderate generalized cardiomegaly with a vertebral heart score of 9.8 with the reference range up to 8.5. Left atrial enlargement is noted on the orthogonal view. A moderate vascular lung pattern with perihilar accentuation is seen. No significant bronchial markings are noted.

RADIOGRAPHIC DIAGNOSIS

- Moderate cardiomegaly with atrial enlargement and vascular lung pattern - suspect emerging cardiogenic pulmonary edema.

INTERPRETATION OF THE FINDINGS & FURTHER RECOMMENDATIONS

The radiographic findings support congestive heart failure with incipient cardiogenic pulmonary edema. Moderate enlargement of the cardiac silhouette with left atrial enlargement is seen. No significant bronchial markings are noted, and the mediastinum and trachea present within normal limits. A full cardiac echo is recommended for further definition if not performed already. The use of diuretics could be considered.

INTERPRETED BY

Nele Eley, DVM
Dr. med. Vet. DipECVDI

HOSPITAL NAME

Woodridge
Veterinary Clinic

REFERRING VET

Dr. Anique McCrea-
Spence

INVOICE

54061

DATE

9-10-22



PATIENT

Marvin Boyer

SPECIES

Feline

BREED

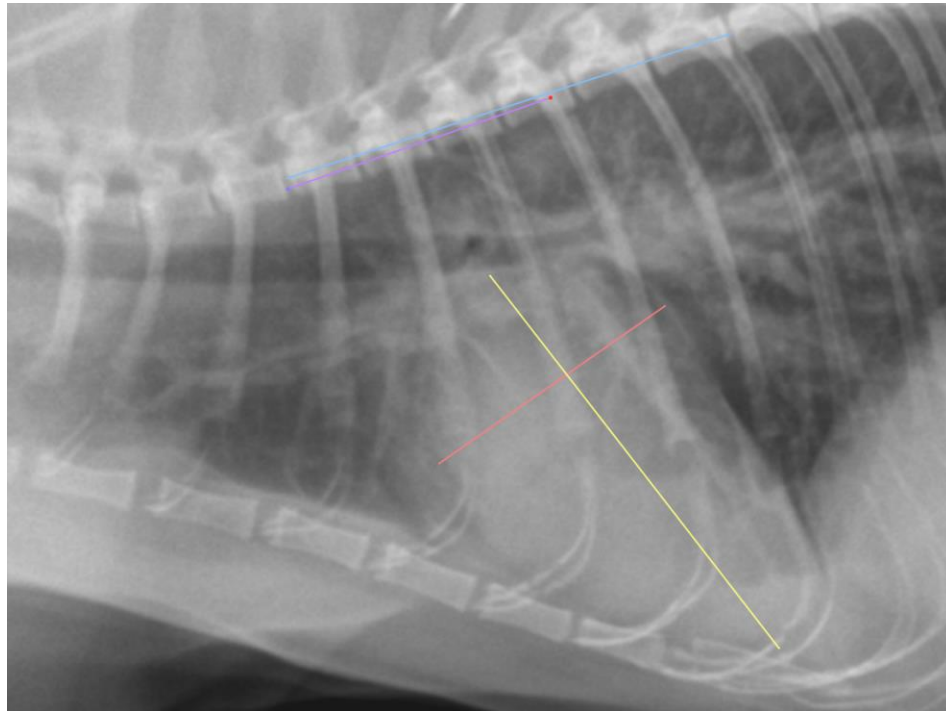
Siamese

SEX

MN

AGE

3 Years



INTERPRETED BY

Nele Eley, DVM
Dr. med. Vet. DipECVDI

The information and recommendations provided are based on the images presented by the referring veterinarian/sonographer. No evaluation can be communicated regarding pathology that was not visible in the image/video clips provided.

Thank you for this referral. If the clinical or image interpretation does not parallel your findings or if I can be of any further assistance please contact me.

HOSPITAL NAME

Woodridge
Veterinary Clinic

Nele Eley, DVM, Dr. med. vet., DipECVDI
European Specialist in Veterinary Diagnostic Imaging, Cert. Radiology,
Senior lecturer University of Giessen, Germany, Veterinary Faculty, Department of Radiology
Nele.Eley@sonopath.com

REFERRING VET

Dr. Anique McCrea-
Spence

INVOICE

54061

DATE

9-10-22