

**PATIENT**

Sable Hall

**PRESENTING CLINICAL SIGNS**

Limping on right hind for the past week  
Abnormal PE/Chem/CBC/UA Results: 4/5 RH LAME, PAIN ON ANY EXTENSION OF RIGHT CF JOINT / LOWER SPINE. NORMAL SPINAL REFLEXES RH, No loss of proprioception IN OTHER THREE, NOT ABLE TO TEST IN RH.

**SPECIES**

Canine

**RADIOGRAPHIC STUDY OF THE PELVIS**

Ventrodorsal and lateral views totaling 2 images available for review.

**BREED**

Labrador Retriever

**RADIOGRAPHIC FINDINGS**

A monostotic aggressive osteolytic lesion of the right proximal femur is seen with permeative lysis within the proximal metaphysis and epiphysis of the femur as well as a large amount of spiculated periosteal new bone formation and multifocal cortical bone thinning. The transition zone to the unaffected bone within the proximal diaphysis of the right femur is long and indistinct. The changes do not cross the limits of the femur. The pelvis is unaffected.

**SEX**

Spayed

The right hind limb presents severe atrophy of its musculature.

**AGE**

12 Years, 6 Months

**RADIOGRAPHIC DIAGNOSIS**

- Monostotic aggressive osteolytic lesion of the right proximal femur.
- Severe disuse atrophy of the right hind limb musculature.

**INTERPRETED BY**

Nele Eley, DVM  
Dr. med. Vet. DipECVDI

**INTERPRETATION OF THE FINDINGS & FURTHER RECOMMENDATIONS**

The radiographic findings are highly suggestive for primary neoplasia of bone within the right proximal femur. Osteosarcoma is a primary differential diagnosis. Chondrosarcoma and other mesenchymal neoplasia as well as metastatic disease and round cell neoplasia are potential but less likely differential diagnoses.

**HOSPITAL NAME**

Elizabeth Animal  
Hospital

Note the presence of prolonged disuse of the right hind limb with atrophy of its musculature.

Full staging could be considered in case the owner is interested in pursuing further treatment such as and including amputation.

**REFERRING VET**

Leon Anderson, DVM

**INVOICE**

53921

**DATE**

9-1-22



**PATIENT**

Sable Hall

**SPECIES**

Canine

**BREED**

Labrador Retriever

**SEX**

Spayed

**AGE**

12 Years, 6 Months

**INTERPRETED BY**

Nele Eley, DVM  
Dr. med. Vet. DipECVDI

**HOSPITAL NAME**

Elizabeth Animal  
Hospital

**REFERRING VET**

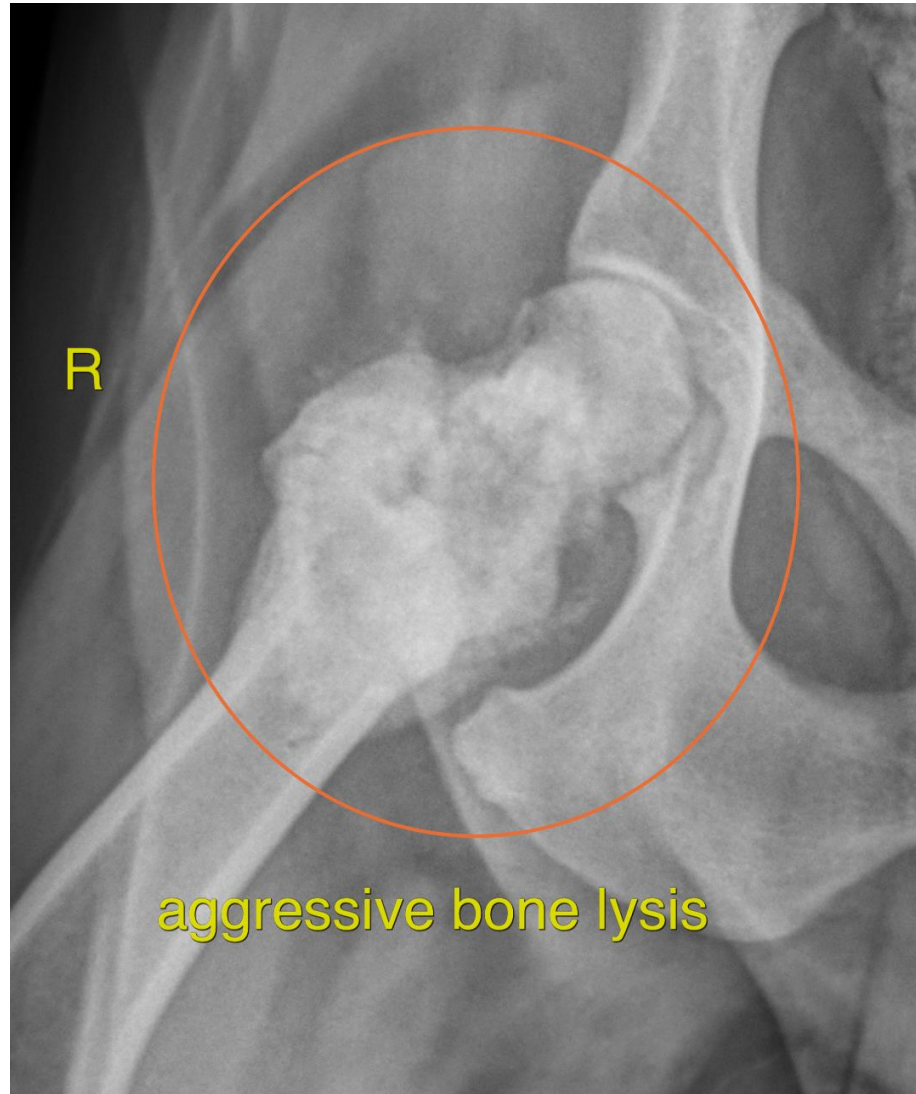
Leon Anderson, DVM

**INVOICE**

53921

**DATE**

9-1-22



The information and recommendations provided are based on the images presented by the referring veterinarian/sonographer. No evaluation can be communicated regarding pathology that was not visible in the image/video clips provided.

Thank you for this referral. If the clinical or image interpretation does not parallel your findings or if I can be of any further assistance please contact me.

**Nele Eley**, DVM, Dr. med. vet., DipECVDI  
European Specialist in Veterinary Diagnostic Imaging, Cert. Radiology,  
Senior lecturer University of Giessen, Germany, Veterinary Faculty, Department of Radiology  
Nele.Eley@sonopath.com