


PATIENT PRESENTING CLINICAL SIGNS

Amadeux Williams 1 month of weight loss and ascites with good appetite. Echo wnl. Mild hypoproteinemia and hypoglobulinemia, normal albumin. On prednisone BID, diet GI low fat.

SPECIES COMPUTED TOMOGRAPHIC STUDY OF THE THORAX & ABDOMEN

Canine Plain study of the thorax and plain and post-contrast studies of the abdomen provided for review. Limited assessment of the abdomen owing to poor contrast resolution.

BREED COMPUTED TOMOGRAPHIC FINDINGS

Great Dane Abdomen
 A large amount of free peritoneal effusion is seen, which reduces the serosal detail significantly, even on the post-contrast study.

SEX No mass effect is identified in the abdomen.

Female The kidneys present within normal limits.

AGE No structural gastrointestinal abnormality can be seen.

6 Years There is no evidence of lymphadenomegaly noted.

T13-L4 spondyloses are seen as well as lumbosacral spondylosis deformans.

INTERPRETED BY Thorax

The bony structures are within normal limits.

Nele Eley (Ondreka),
 DVM Dr. med. vet.,
 DipECVDI

The sternal, cranial mediastinal and tracheobronchial lymph nodes are small elongated with a normal short-to-long-axis-ratio is < 0.5.

HOSPITAL NAME

Aloha Pet & Bird
 Hospital

The cardiovascular structures including the pulmonary vasculature are within normal limits.

The bronchial tree presents with regular branching and tapers uniformly towards the periphery as expected, the bronchial walls are thin and smooth. The bronchus-to-artery ratio is within normal limits.

The lung parenchyma presents the expected architecture and attenuation behavior.

REFERRING VET

Dr. Smith

Small incidental gas pockets are seen within the esophageal lumen, there is no evidence of abnormal dilation.

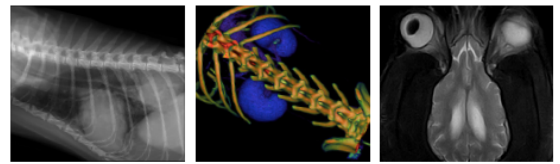
COMPUTED TOMOGRAPHIC DIAGNOSIS
INVOICE

44539

- Limited study with a large amount of free peritoneal effusion. No other structural abdominal pathology identified.
- Normal thorax.
- Multiple spondyloses.

DATE

8/9/23



PATIENT INTERPRETATION OF FINDINGS & FURTHER RECOMMENDATIONS

Amadeux Williams

Ultrasound and/or standard CT may have greater sensitivity in this patient for more detailed assessment of the abdominal organs owing to the presence of large amounts of peritoneal effusion. As far as assessable, there was no evidence of an abdominal mass effect, vascular anomalies or lymphadenomegaly.

SPECIES

Canine

The effusion may represent transudate, modified transudate, or exudate. Correlation with fluid analysis is recommended.

BREED

Great Dane

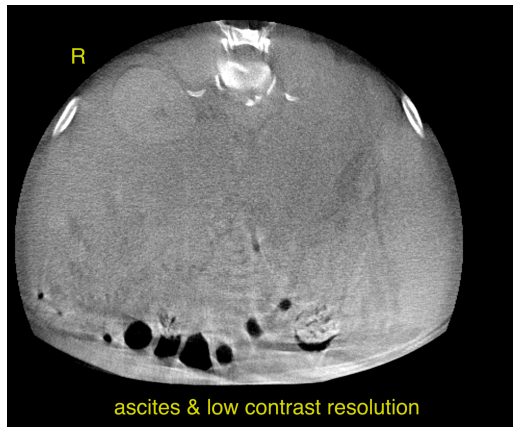
The CT presentation of the thorax was within age related normal limits.

SEX

Female

AGE

6 Years



INTERPRETED BY

Nele Eley (Ondreka),
DVM Dr. med. vet.,
DipECVDI

The information and recommendations provided are based on the images presented by the referring veterinarian. No evaluation can be communicated regarding pathology that was not visible in the image/video clips provided.

Thank you for this referral. If the clinical or image interpretation does not parallel your findings or if I can be of any further assistance please contact me.

HOSPITAL NAME

Aloha Pet & Bird
Hospital

Nele Eley (Ondreka), DVM, Dr. med. vet., DipECVDI
European Specialist in Veterinary Diagnostic Imaging, Cert. Radiology,
Senior lecturer University of Giessen/Germany, Veterinary Faculty, Department of Radiology.
Nele.Eley@sonopath.com

REFERRING VET

Dr. Smith

INVOICE

44539

DATE

8/9/23