


PATIENT PRESENTING CLINICAL SIGNS

Alfie McChesney Lethargy, not eating or drinking, panting.
 Abnormal PE/Chem/CBC/UA Results: Blood work didn't show major abnormalities

SPECIES RADIOGRAPHIC STUDY OF THE THORAX

Feline Right lateral and ventrodorsal whole body views totaling 3 images available for review. Thoracic interpretation only requested.

BREED RADIOGRAPHIC FINDINGS

DSH The degree of pulmonary inflation is deep. The bronchopulmonary structures present within normal limits.

SEX

The chest is expanded with ventrally diverging ribs.

Neutered Male

The radiographic presentation of the cardiac silhouette is within normal limits. Vertebral heart score is 7.3, which is within the reference range. No evidence of atrial enlargement. There is no evidence of abnormal mediastinal widening.

AGE

Course and width of the trachea are considered within normal limits.

5 Years

The thoracic boundaries present within normal limits.

Gastric aerophagia is noted.

INTERPRETED BY

Nele Eley (Ondreka),
 DVM Dr. med. vet.,
 DipECVDI

RADIOGRAPHIC DIAGNOSIS

- Normal radiographic presentation of the bronchopulmonary and cardiovascular structures
- Deep inhalation of the lung
- Aerophagia

HOSPITAL NAME

St. Catharine's AH

INTERPRETATION OF FINDINGS & FURTHER RECOMMENDATIONS

No bronchopulmonary or cardiovascular abnormality was seen radiographically. Early bronchopulmonary disease cannot be ruled out entirely since the radiographic findings may lag behind the clinical course of the disease. Nevertheless, the radiographic presentation of the lung is within normal limits at this point. Cardiopathy with arrhythmia cannot be ruled out radiographically. The radiographs however do rule out cardiomegaly, atrial enlargement, and volume overload. A more detailed assessment can be achieved by means of a cardiac echo and ECG, if indicated based on the clinical examination. The aerophagia indicates respiratory distress or general stress, anxiety, pain, which can also explain the deep inflation of the lung.

REFERRING VET

Dr. Adel Williams

INVOICE

44580

DATE

8/9/23



PATIENT

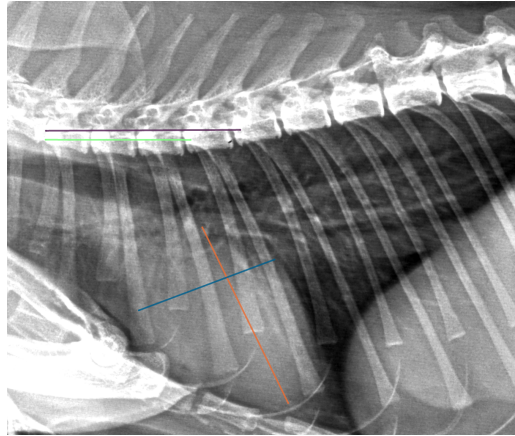
Alfie McChesney

SPECIES

Feline

BREED

DSH



SEX

Neutered Male

AGE

5 Years

The information and recommendations provided are based on the images presented by the referring veterinarian. No evaluation can be communicated regarding pathology that was not visible in the image/video clips provided.

Thank you for this referral. If the clinical or image interpretation does not parallel your findings or if I can be of any further assistance please contact me.

Nele Eley (Ondreka), DVM, Dr. med. vet., DipECVDI
European Specialist in Veterinary Diagnostic Imaging, Cert. Radiology,
Senior lecturer University of Giessen/Germany, Veterinary Faculty, Department of Radiology.
Nele.Eley@sonopath.com

INTERPRETED BY

Nele Eley (Ondreka),
DVM Dr. med. vet.,
DipECVDI

HOSPITAL NAME

St. Catharine's AH

REFERRING VET

Dr. Adel Williams

INVOICE

44580

DATE

8/9/23