

PATIENT PRESENTING CLINICAL SIGNS

Zoe Cooke 2+ month history of Right rear lameness Exam: Knee flexion pain + cranial drawer Left knee normal

ULTRASONOGRAPHIC STUDY OF THE STIFLES

SPECIES

Right Stifle
 Canine A moderate amount of effusion is seen within the supra- and infrapatellar recesses of the right stifle joint. Moderate periarticular osteophytes are seen. The cranial cruciate ligament presents as a stump of echogenic fibers at the intercondylar eminence of the tibia, surrounded by a hypoechoic halo. Visible parts of the medial meniscus present within normal limits.

BREED

Airedale Scant effusion is noted within the left stifle joint with signs of early degenerative joint disease. The caudal and cranial cruciate ligament, however, are continuous and well delineated. No evidence of meniscopathy is seen at this point.

SEX

Spayed Female

ULTRASONOGRAPHIC DIAGNOSIS

- Moderate right stifle osteoarthritis with ultrasonographic signs of cranial cruciate ligament pathology.
- No evidence of meniscopathy
- Early degenerative joint disease of the left stifle joint

AGE

10 Years

INTERPRETATION OF FINDINGS & FURTHER RECOMMENDATIONS

The ultrasonographic findings suggest presence of full rupture of the right cranial cruciate ligament. At this point, there is no evidence of concomitant meniscopathy. Moderate osteoarthritic changes are seen. Surgical intervention could be considered in order to address the presumed biomechanical instability of the right stifle joint and prevent further damage to the articular structures such as the menisci.

INTERPRETED BY

Nele Eley (Ondreka),
 DVM Dr. med. vet.,
 DipECVDI

HOSPITAL NAME

Colorado Animal
 Specialty &
 Emergency

REFERRING VET

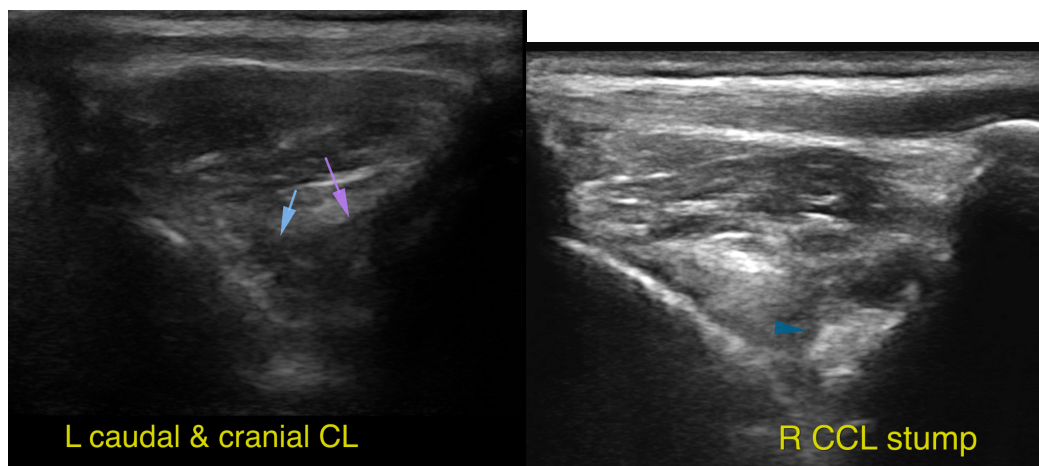
Dr. James Gaynor

INVOICE

44525

DATE

8/8/23



L caudal & cranial CL

R CCL stump



PATIENT

Zoe Cooke

The information and recommendations provided are based on the images presented by the referring veterinarian. No evaluation can be communicated regarding pathology that was not visible in the image/video clips provided.

SPECIES

Canine

Thank you for this referral. If the clinical or image interpretation does not parallel your findings or if I can be of any further assistance please contact me.

BREED

Airedale

Nele Eley (Ondreka), DVM, Dr. med. vet., DipECVDI
European Specialist in Veterinary Diagnostic Imaging, Cert. Radiology,
Senior lecturer University of Giessen/Germany, Veterinary Faculty, Department of Radiology.
Nele.Eley@sonopath.com

SEX

Spayed Female

AGE

10 Years

INTERPRETED BY

Nele Eley (Ondreka),
DVM Dr. med. vet.,
DipECVDI

HOSPITAL NAME

Colorado Animal
Specialty &
Emergency

REFERRING VET

Dr. James Gaynor

INVOICE

44525

DATE

8/8/23