


PATIENT PRESENTING CLINICAL SIGNS

Midnight Goodwin-Bell
 Persistent coughing for 1 week. Up to date on Bordetella vaccination

RADIOGRAPHIC STUDY OF THE THORAX

SPECIES Right/left lateral and ventrodorsal views available for review.

Canine **RADIOGRAPHIC FINDINGS**

The degree of pulmonary inflation is moderate. A mild generalized bronchointerstitial lung pattern with occasional caudodorsally accentuated peribronchial cuffing is seen.

BREED There is no evidence of mediastinal widening.

Doberman The cardiac silhouette presents within normal limits. Vertebral heart score is 10.2 with a reference range up to 10.5.

SEX Course and width of the trachea are considered within normal limits.

Spayed Female Thoracic boundaries present within normal limits.

AGE Mild gastric aerophagia is noted and a mild amount of gastric gravel.

2 Years **RADIOGRAPHIC DIAGNOSIS**

- Mild generalized bronchointerstitial lung pattern
- Normal radiographic presentation of the cardiovascular structures

INTERPRETED BY

Nele Eley (Ondreka),
 DVM Dr. med. vet.,
 DipECVDI

INTERPRETATION OF FINDINGS & FURTHER RECOMMENDATIONS

The radiographic findings suggest potential for lower airway disease. Infectious bronchitis such as viral, bacterial, mixed, or parasitic is considered most likely. Allergic bronchopneumopathy cannot be ruled out entirely as a differential diagnosis. Further definition by means of airway endoscopy with bronchoalveolar lavage and lungworm testing could be considered if not already performed.

HOSPITAL NAME

DTLA Vets

REFERRING VET

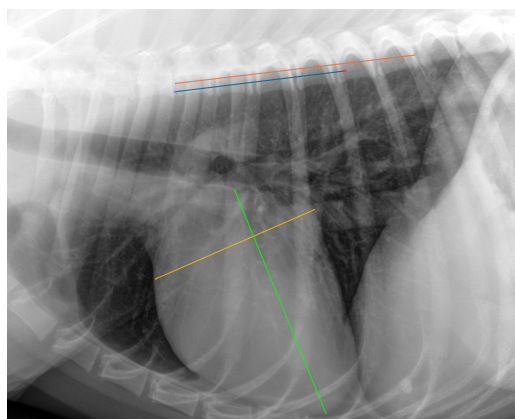
Dr. Amini

INVOICE

44528

DATE

8/8/23





PATIENT

Midnight Goodwin-
Bell

The information and recommendations provided are based on the images presented by the referring veterinarian. No evaluation can be communicated regarding pathology that was not visible in the image/video clips provided.

SPECIES

Canine

Thank you for this referral. If the clinical or image interpretation does not parallel your findings or if I can be of any further assistance please contact me.

BREED

Doberman

Nele Eley (Ondreka), DVM, Dr. med. vet., DipECVDI
European Specialist in Veterinary Diagnostic Imaging, Cert. Radiology,
Senior lecturer University of Giessen/Germany, Veterinary Faculty, Department of Radiology.
Nele.Eley@sonopath.com

SEX

Spayed Female

AGE

2 Years

INTERPRETED BY

Nele Eley (Ondreka),
DVM Dr. med. vet.,
DipECVDI

HOSPITAL NAME

DTLA Vets

REFERRING VET

Dr. Amini

INVOICE

44528

DATE

8/8/23