
PATIENT PRESENTING CLINICAL SIGNS

Luna Rhodes Two day history of excessive panting, appetite and all other parameters WNL at home, no vomiting. Did live in Kansas in 2018 to 2019, now lives in NM

SPECIES Abnormal PE/Chem/CBC/UA Results: PE showed mild asynchronous pulses, normal heart sounds, lung sounds increased, CRT 2 seconds, otherwise WNL CBC/Chemistry WNL

Canine

RADIOGRAPHIC STUDY OF THE THORAX

BREED Right/left lateral and ventrodorsal views of the thorax totaling 4 images provided for review.

Boxer

RADIOGRAPHIC FINDINGS

Multiple thoracic spondyloses are seen.

SEX There are mild signs of elbow osteoarthritis.

Spayed Female Course and width of the trachea are considered within normal limits.

AGE

Mild esophageal and gastric aerophagia are seen.

8 Years

The degree of pulmonary inflation is deep. A moderate generalized interstitial lung pattern with occasional peribronchial cuffing and multiple punctate opaque nodules are seen and evenly distributed throughout the lung.

INTERPRETED BY

The cardiac silhouette presents within normal limits. Vertebral heart score is 10.2.

Nele Eley (Ondreka),
 DVM Dr. med. vet.,
 DipECVDI

Pulmonary vasculature presents within normal limits.

There is no evidence of mediastinal widening.

HOSPITAL NAME

Petroglyph AH

The liver is relatively small in size.

RADIOGRAPHIC DIAGNOSIS

- Moderate generalized unstructured interstitial lung pattern with peribronchial cuffing
- Aerophagia as a sign of respiratory distress
- Multiple spondyloses

REFERRING VET

Dr. Whitney Jones

INTERPRETATION OF FINDINGS & FURTHER RECOMMENDATIONS
INVOICE

44533

A diffuse interstitial lung pattern is noted. Differential diagnosis includes interstitial pneumonia, unclassified non-infectious interstitial lung disease, and less likely interstitial infiltrate with round cells. Further definition by means of airway endoscopy with airway sampling could be considered. Direct fine needle aspiration of the lung under ultrasonographic guidance can be considered as an alternative should endoscopy not be an option in this patient.

DATE

8/8/23



PATIENT

Luna Rhodes

SPECIES

Canine

BREED

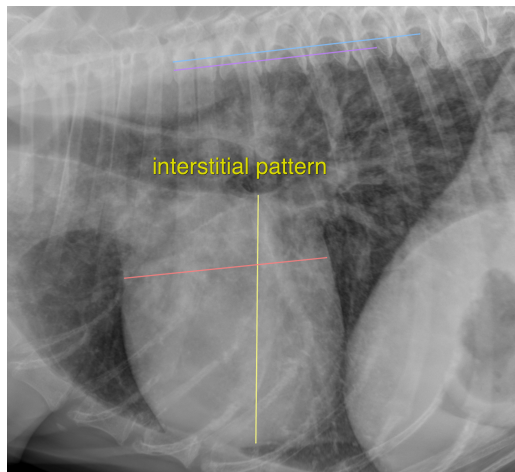
Boxer

SEX

Spayed Female

AGE

8 Years



The information and recommendations provided are based on the images presented by the referring veterinarian. No evaluation can be communicated regarding pathology that was not visible in the image/video clips provided.

Thank you for this referral. If the clinical or image interpretation does not parallel your findings or if I can be of any further assistance please contact me.

INTERPRETED BY

Nele Eley (Ondreka),
DVM Dr. med. vet.,
DipECVDI

Nele Eley (Ondreka), DVM, Dr. med. vet., DipECVDI
European Specialist in Veterinary Diagnostic Imaging, Cert. Radiology,
Senior lecturer University of Giessen/Germany, Veterinary Faculty, Department of Radiology.
Nele.Eley@sonopath.com

HOSPITAL NAME

Petroglyph AH

REFERRING VET

Dr. Whitney Jones

INVOICE

44533

DATE

8/8/23