

PATIENT PRESENTING CLINICAL SIGNS

Frisco Gray 5 weeks post shoulder trauma. Has had Acupuncture. Electroacupuncture. Laser daily. One alpha 2 series. Methocarbamol. Gabapentin. Osteon. Rom exercises. He bears weight. Walks but still also hops frequently. My concern is still the pocket of effusion cranial biceps preventing extension flexion. Rads appear that glenoid process has healed. Impression is that effusion causing much decrease rom... Trying to best determine plan for potential steroid intervention vs. other recommendations.

SPECIES

Equine

ULTRASONOGRAPHIC STUDY OF THE LEFT SHOULDER

BREED

Compared to prior study.

Miniature Horse

ULTRASONOGRAPHIC FINDINGS

SEX

Swelling and heterogeneity of the left biceps tendon are stationary. Anechoic effusion within the bicipital tendon sheath and shoulder joint are stationary as well. Periarticular bone remodeling of the glenoid cavity and humeral head are seen.

Gelding

ULTRASONOGRAPHIC DIAGNOSIS

AGE

- Subacute biceps tendon injury of the left shoulder with joint effusion and tenosynovitis
- Periarticular bone remodeling secondary to osseous injury with articular involvement versus secondary osteoarthritis.

17 Years 6 Months

INTERPRETATION OF FINDINGS & FURTHER RECOMMENDATIONS

INTERPRETED BY

Nele Eley (Ondreka),
DVM Dr. med. vet.,
DipECVDI

Stationary signs of biceps injury with tendon sheath and joint effusion are seen in the left shoulder. The changes may represent partial rupture or direct traumatic injury of the tendon. The periarticular bone remodeling further suggests the potential for concurrent osseous injury or labrum injury with callus formation and/or early degenerative joint disease. A tendency of healing other than the tendon and periarticular bone remodeling is not observed at this point yet.

HOSPITAL NAME

Rivers Edge PMC

REFERRING VET

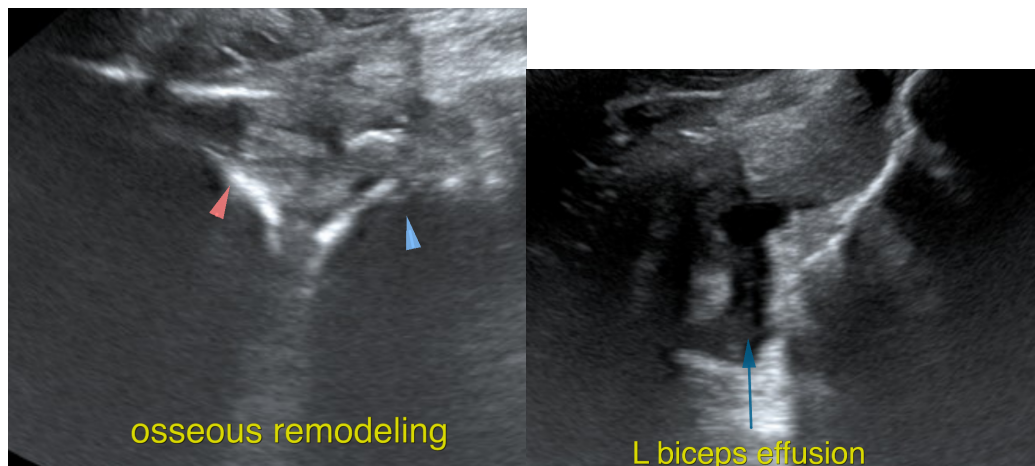
Dr. Leah Gray

INVOICE

44527

DATE

8/8/23



osseous remodeling

L biceps effusion



PATIENT

Frisco Gray

The information and recommendations provided are based on the images presented by the referring veterinarian. No evaluation can be communicated regarding pathology that was not visible in the image/video clips provided.

SPECIES

Equine

Thank you for this referral. If the clinical or image interpretation does not parallel your findings or if I can be of any further assistance please contact me.

BREED

Miniature Horse

Nele Eley (Ondreka), DVM, Dr. med. vet., DipECVDI
European Specialist in Veterinary Diagnostic Imaging, Cert. Radiology,
Senior lecturer University of Giessen/Germany, Veterinary Faculty, Department of Radiology.
Nele.Eley@sonopath.com

SEX

Gelding

AGE

17 Years 6 Months

INTERPRETED BY

Nele Eley (Ondreka),
DVM Dr. med. vet.,
DipECVDI

HOSPITAL NAME

Rivers Edge PMC

REFERRING VET

Dr. Leah Gray

INVOICE

44527

DATE

8/8/23