



PATIENT

Stash Thrush

PRESENTING CLINICAL SIGNS

owner has noticed coughing at home and in clinic can hear musical tones over left lung field

SPECIES

Feline

RADIOGRAPHIC STUDY OF THE THORAX

Right/left lateral and ventrodorsal views totaling 3 images available for review.

BREED

DSH

The ribcage is expanded and barrel shaped.

Wide lumbodiaphragmatic angles and a flat diaphragmatic cupola indicate deep pulmonary inflation suggesting air trapping. A moderate generalized bronchial lung pattern with mild tree-in-bud pattern is noted.

SEX

MN

The radiographic presentation of the cardiac silhouette and trachea is within normal limits.

No evidence of mediastinal widening is seen.

AGE

12 Years

RADIOGRAPHIC DIAGNOSIS

- Moderate generalized bronchial lung pattern with air trapping.

INTERPRETED BY

Nele Eley, DVM
Dr. med. Vet. DipECVDI

INTERPRETATION OF THE FINDINGS & FURTHER RECOMMENDATIONS

The radiographic findings are suggesting for allergic lower airway syndrome (feline asthma). Infectious bronchitis cannot be ruled out entirely as a differential diagnosis. Consider a clinical trial of treatment for feline asthma versus airway endoscopy with airway sampling for further definition.

HOSPITAL NAME

Sylvan Lake
Veterinary Clinic

No radiographic evidence of cardiovascular pathology was found.

REFERRING VET

Dr. Sandy Jameson

INVOICE

53322

DATE

8-8-22



PATIENT

Stash Thrush

SPECIES

Feline

BREED

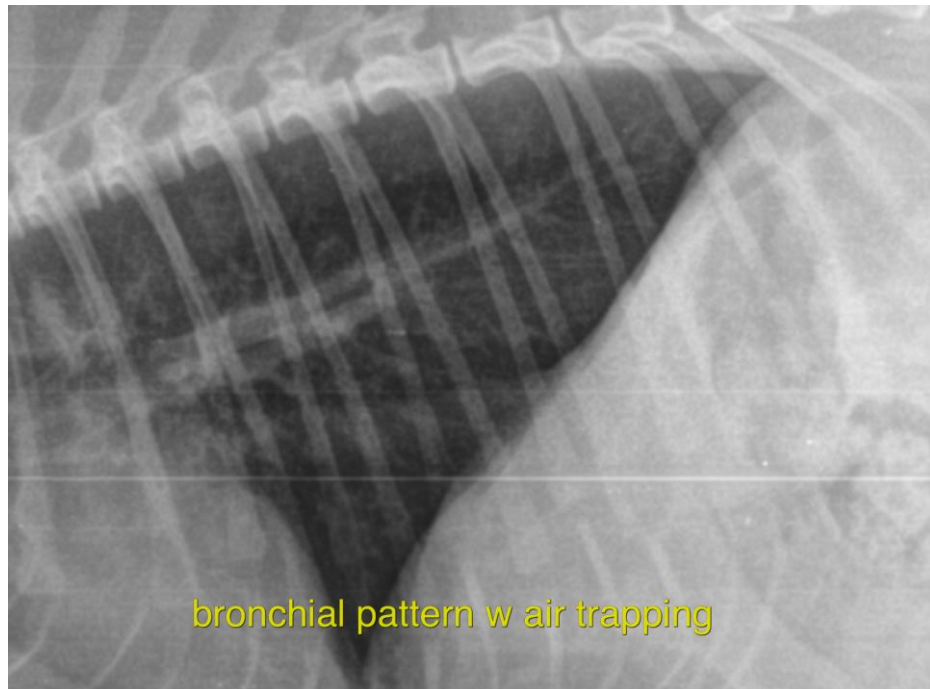
DSH

SEX

MN

AGE

12 Years



INTERPRETED BY

Nele Eley, DVM
Dr. med. Vet. DipECVDI

The information and recommendations provided are based on the images presented by the referring veterinarian/sonographer. No evaluation can be communicated regarding pathology that was not visible in the image/video clips provided.

Thank you for this referral. If the clinical or image interpretation does not parallel your findings or if I can be of any further assistance please contact me.

HOSPITAL NAME

Sylvan Lake
Veterinary Clinic

Nele Eley, DVM, Dr. med. vet., DipECVDI
European Specialist in Veterinary Diagnostic Imaging, Cert. Radiology,
Senior lecturer University of Giessen, Germany, Veterinary Faculty, Department of Radiology
Nele.Eley@sonopath.com

REFERRING VET

Dr. Sandy Jameson

INVOICE

53322

DATE

8-8-22