

**PATIENT**

Sharon Burkhouse

PRESENTING CLINICAL SIGNS

Chronic vomiting and inappetance.
Abnormal PE/Chem/CBC/UA Results: WNL

SPECIES

Feline

RADIOGRAPHIC STUDY OF THE ABDOMEN

Single right lateral view of the thorax and abdomen available for review.

Abdominal read requested.

BREED

Domestic Longhair

RADIOGRAPHIC FINDINGS

The patient has thoracolumbar and lumbosacral transitional vertebrae. Degenerative lumbosacral stenosis with lumbosacral spondylosis deformans is noted.

SEX

FS

The stomach contains a mild amount of ingesta and gas.

The small intestinal loops are evenly distributed throughout the mid abdomen and mildly turgid in appearance. Presence of generalized wall thickening cannot be ruled out.

AGE

12 Years

A large amount of highly inspissated fecal matter is seen in the caudal descending colon.

The urinary bladder is moderately distended.

INTERPRETED BY

Nele Eley, DVM
Dr. med. Vet. DipECVDI

The kidneys and liver present within normal limits.

RADIOGRAPHIC DIAGNOSIS

- Small intestinal maldigestion pattern.
- Mild coprostasis.
- Degenerative lumbosacral stenosis with transitional vertebrae.

HOSPITAL NAME

New Bridge
Veterinary Practice

INTERPRETATION OF THE FINDINGS & FURTHER RECOMMENDATIONS

In light of the chronic nature of the patient's clinical signs and suspicious radiographic presentation of the small intestine, further definition by means of abdominal ultrasound would be prudent in this patient. However, it has to be noted that the assessment of wall thickness is purely subjective on radiographs and radiographs do not offer great diagnostic accuracy in this context so that the presence of wall thickening should not be considered given in this or any other patient based on radiographic impressions only.

REFERRING VET

Dr. Abina Glennon

INVOICE

53326

DATE

8-8-22



PATIENT

Sharon Burkhouse

SPECIES

Feline

BREED

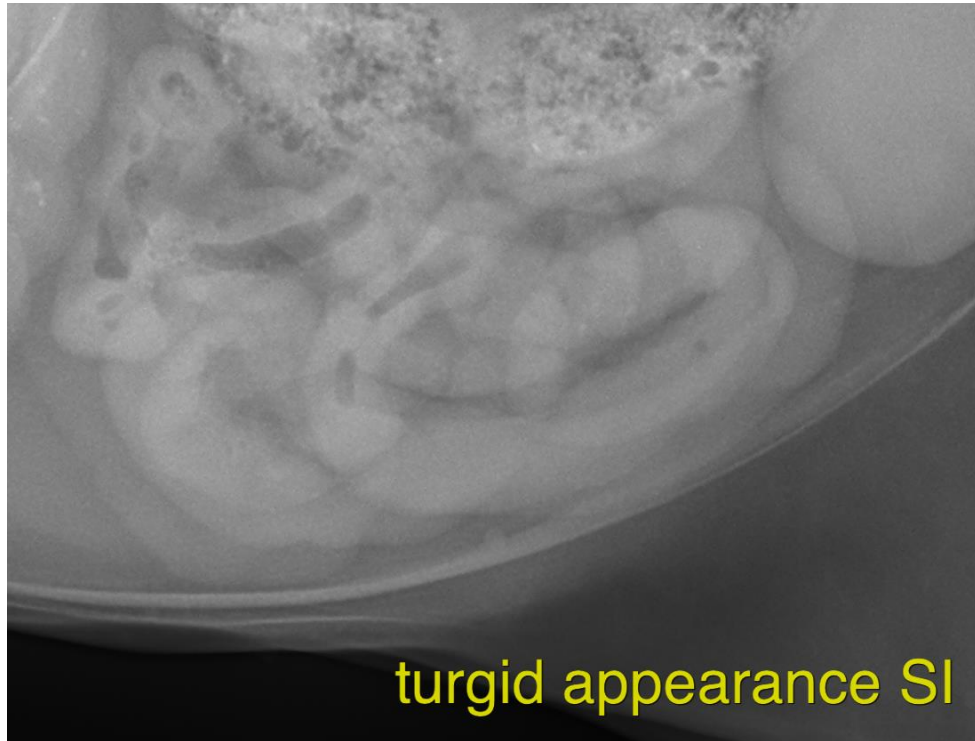
Domestic Longhair

SEX

FS

AGE

12 Years



turgid appearance SI

INTERPRETED BY

Nele Eley, DVM
Dr. med. Vet. DipECVDI

The information and recommendations provided are based on the images presented by the referring veterinarian/sonographer. No evaluation can be communicated regarding pathology that was not visible in the image/video clips provided.

HOSPITAL NAME

New Bridge
Veterinary Practice

Thank you for this referral. If the clinical or image interpretation does not parallel your findings or if I can be of any further assistance please contact me.

REFERRING VET

Dr. Abina Glennon

Nele Eley, DVM, Dr. med. vet., DipECVDI
European Specialist in Veterinary Diagnostic Imaging, Cert. Radiology,
Senior lecturer University of Giessen, Germany, Veterinary Faculty, Department of Radiology
Nele.Eley@sonopath.com

INVOICE

53326

DATE

8-8-22