

**PATIENT**

Nahla Bohannon

PRESENTING CLINICAL SIGNS

Recent onset R-sided epistaxis, improved following Yunnan Bai Yao administration. Abnormal PE/Chem/CBC/UA Results: PE- R-sided epistaxis Chem: ALT= 220 (10-118), otherwise WNL T4- WNL

SPECIES

Canine

COMPUTED TOMOGRAPHIC STUDY OF THE HEAD

Plain and post contrast studies available for review.

BREED

Dutch Shepherd

COMPUTED TOMOGRAPHIC FINDINGS

A mass that is composed of loosely arranged soft tissue with strong heterogeneous contrast enhancement and multifocal new bone formation is seen within the right nasal cavity. The mass occupies the mid and caudal third of the right nasal cavity and focal interruption of the osseous nasal septum with extension into the left nasal cavity is seen in the caudal third of the nose. The cribriform plate is intact. The mass extends into the nasal fundus. The rostral parts of the right nasal cavity present extensive turbinate destruction and fluid accumulation. The right frontal sinus is filled with fluid attenuating material.

SEX

FS

The medial retropharyngeal lymph nodes present within normal limits.

AGE

10 Years

COMPUTED TOMOGRAPHIC DIAGNOSIS

- Soft tissue mass with aggressive biological behavior and multifocal new bone formation within the mid and caudal third of the right nasal cavity.

INTERPRETED BY

Nele Eley, DVM
Dr. med. Vet. DipECVDI

INTERPRETATION OF THE FINDINGS & FURTHER RECOMMENDATIONS

The CT findings are highly suggestive for a nasal neoplasia. Consider chondrosarcoma and adenocarcinoma primary differentials. However, lymphosarcoma and other neoplasia including soft tissue sarcoma cannot be ruled out entirely. The findings are not typical for destructive rhinitis even though fungal rhinitis with mineralizing granuloma cannot be ruled out entirely. Further definition by means of rhinoscopy with sampling for histology and culture is recommended.

HOSPITAL NAME

Healing Spirit Animal
Wellness

REFERRING VET

Desen Ertunc

INVOICE

53332

DATE

8-8-22



PATIENT

Nahla Bohannon

SPECIES

Canine

BREED

Dutch Shepherd

SEX

FS

AGE

10 Years

INTERPRETED BY

Nele Eley, DVM
Dr. med. Vet. DipECVDI

HOSPITAL NAME

Healing Spirit Animal
Wellness

REFERRING VET

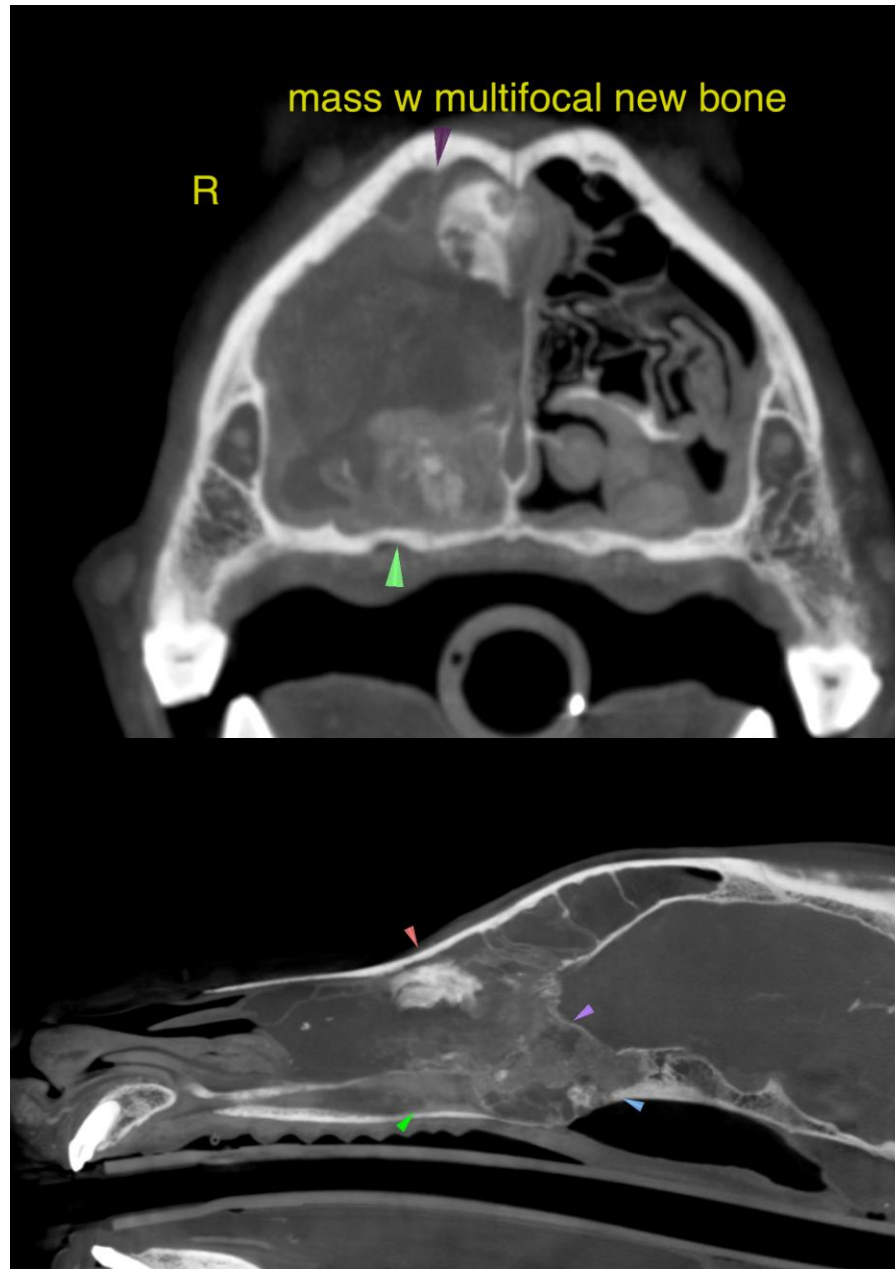
Desen Ertunc

INVOICE

53332

DATE

8-8-22





PATIENT

Nahla Bohannon

The information and recommendations provided are based on the images presented by the referring veterinarian/sonographer. No evaluation can be communicated regarding pathology that was not visible in the image/video clips provided.

Thank you for this referral. If the clinical or image interpretation does not parallel your findings or if I can be of any further assistance please contact me.

SPECIES

Canine

Nele Eley, DVM, Dr. med. vet., DipECVDI
European Specialist in Veterinary Diagnostic Imaging, Cert. Radiology,
Senior lecturer University of Giessen, Germany, Veterinary Faculty, Department of Radiology
Nele.Eley@sonopath.com

BREED

Dutch Shepherd

SEX

FS

AGE

10 Years

INTERPRETED BY

Nele Eley, DVM
Dr. med. Vet. DipECVDI

HOSPITAL NAME

Healing Spirit Animal
Wellness

REFERRING VET

Desen Ertunc

INVOICE

53332

DATE

8-8-22