

**PATIENT**

Daisy (Daisee) Milne

SPECIES

Canine

BREED

Gold Ret

SEX

FS

AGE

9 Years, 4 Months

INTERPRETED BYNele Eley, DVM
Dr. med. Vet. DipECVDI**HOSPITAL NAME**Westview Veterinary
Hospital**REFERRING VET**

Dr. Brian Barnes

INVOICE

53318

DATE

8-8-22

PRESENTING CLINICAL SIGNS

Had a recent acute onset favoring of the right stifle. Has had previous TTA on the other knee in 2017

Abnormal PE/Chem/CBC/UA Results: Positive Cranial drawer, and CTT. Asso medial buttress and osteophytes, a more chronic knee with an acute presentation, Had TTA and Meniscus appeared normal

ULTRASONOGRAPHIC FINDINGS**Right Stifle**

Moderate thickening of the synovium and joint capsule is seen. There is a moderate amount of anechoic effusion within the supra- and infra- patellar recesses and a large amount of periarticular osteophytes. Marked heterogeneity of the infrapatellar fat pad is seen.

The cranial cruciate ligament presents as a hyperechoic stump with smooth outline surrounded by a hypoechoic halo at the intercondylar eminence of the tibia.

The medial and lateral menisci are in situ and well delineated. Mild internal increase in echogenicity is seen with no evidence of tissue disruption or displacement.

ULTRASONOGRAPHIC DIAGNOSIS

- Moderate to severe chronic osteoarthritis of the right stifle.
- Full rupture of the right cranial cruciate ligament.

INTERPRETATION OF THE FINDINGS & FURTHER RECOMMENDATIONS

Based on the ultrasonographic presentation, chronic full rupture with an organized stump of the cranial cruciate ligament is suspected. The changes of the menisci are subtle. No overt meniscal tear is seen; however, the changes do suggest presence of degenerative changes within the menisci.



PATIENT

Daisy (Daisee) Milne

SPECIES

Canine

BREED

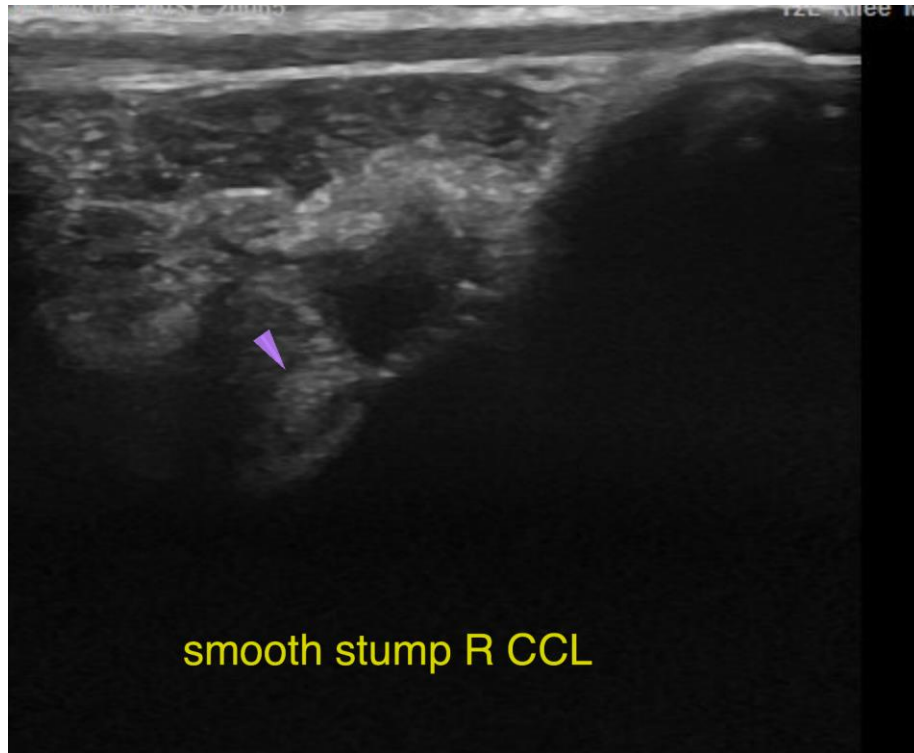
Gold Ret

SEX

FS

AGE

9 Years, 4 Months



INTERPRETED BY

Nele Eley, DVM
Dr. med. Vet. DipECVDI

The information and recommendations provided are based on the images presented by the referring veterinarian/sonographer. No evaluation can be communicated regarding pathology that was not visible in the image/video clips provided.

HOSPITAL NAME

Westview Veterinary
Hospital

Thank you for this referral. If the clinical or image interpretation does not parallel your findings or if I can be of any further assistance please contact me.

Nele Eley, DVM, Dr. med. vet., DipECVDI
European Specialist in Veterinary Diagnostic Imaging, Cert. Radiology,
Senior lecturer University of Giessen, Germany, Veterinary Faculty, Department of Radiology
Nele.Eley@sonopath.com

REFERRING VET

Dr. Brian Barnes

INVOICE

53318

DATE

8-8-22