



PATIENT

Boone Dreyer

PRESENTING CLINICAL SIGNS

Boone was hit by a car today. The owner did not see it happen.
 Abnormal PE/Chem/CBC/UA Results: No murmur or arrhythmia. Eupnic. POSSIBLE DECREASED SOUNDS ON RIGHT SMALL SCRAPER RIGHT SIDE OF MUZZLE WOUND ON DORSAL BACK, APPROX 2 IN LONG 2 ABRASIONS OVER PELVIS 1 CM

SPECIES

Canine

RADIOGRAPHIC STUDY OF THE THORAX & ABDOMEN

Right/left lateral and ventrodorsal views of the thorax and abdomen totaling 7 images available for review.

BREED

German Shorthair Pointer

RADIOGRAPHIC FINDINGS

Number, alignment, and anatomy of the thoracic and lumbar vertebrae appear to be within normal limits. No evidence of traumatic osseous injury is seen.

SEX

MN

Thorax

The ribcage appears to be intact.

There is no evidence of pneumothorax.

AGE

12 Months

The cardiac silhouette is upright and thin. The pulmonary vasculature is thin as well.

There is no evidence of pulmonary contusion or hemorrhage.

INTERPRETED BY

Nele Eley, DVM
 Dr. med. Vet. DipECVDF

Abdomen

The abdominal serosal detail appears to be mildly reduced in the caudal abdomen level with the urinary bladder. The abdominal serosal detail appears to be better in the mid and cranial abdomen.

HOSPITAL NAME

Elizabeth Animal Hospital

Sharply delineated mineral opaque material is seen within the stomach compatible with bones.

RADIOGRAPHIC DIAGNOSIS

REFERRING VET

Kim Allyn, DVM

- No evidence of traumatic osseous injury.
- Mildly reduced serosal detail in the caudal abdomen.
- No evidence of pulmonary injury or pneumothorax.
- Hypovolemia with microcardia and underperfusion of the lung.

INVOICE

53331

INTERPRETATION OF THE FINDINGS & FURTHER RECOMMENDATIONS

The radiographic changes suggest potential for presence of a mild amount of free fluid in the caudal abdomen which may be due to hemorrhage or rupture of a hollow viscus, most likely urinary bladder. Consider a recheck by means of Afast or full abdominal ultrasound with aspiration and analysis of potential fluid should the amount of fluid increase.

DATE

8-8-22



PATIENT

Boone Dreyer

SPECIES

Canine

BREED

German Shorthair
Pointer

SEX

MN

AGE

12 Months

INTERPRETED BY

Nele Eley, DVM
Dr. med. Vet. DipECVDI

HOSPITAL NAME

Elizabeth Animal
Hospital

REFERRING VET

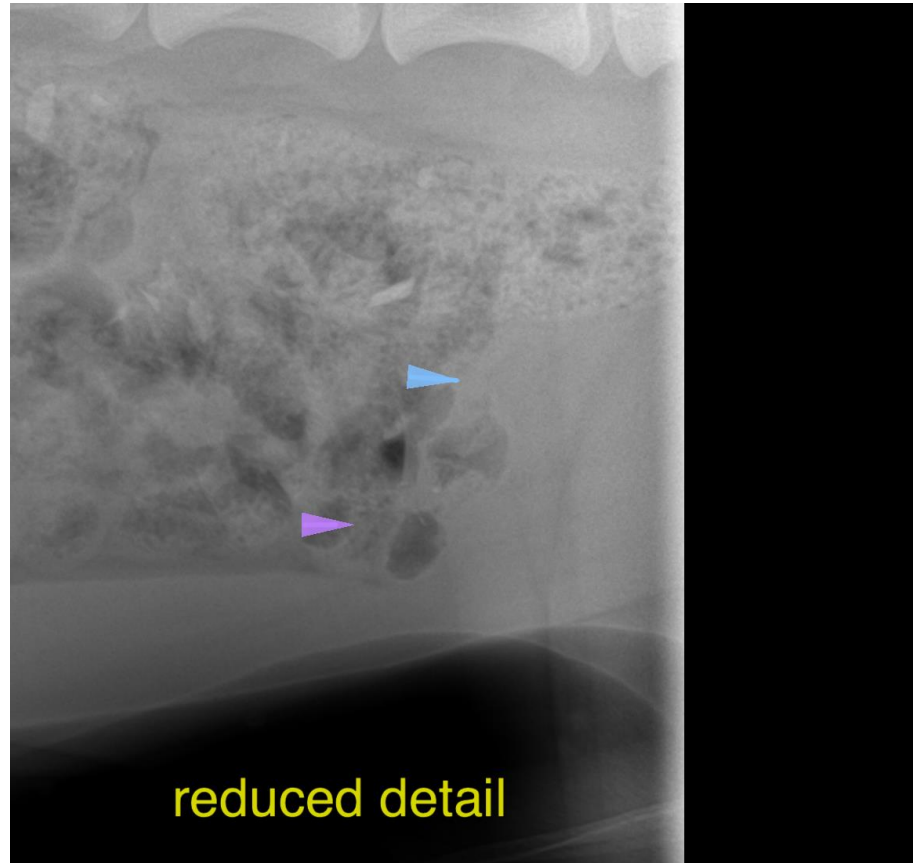
Kim Allyn, DVM

INVOICE

53331

DATE

8-8-22



The information and recommendations provided are based on the images presented by the referring veterinarian/sonographer. No evaluation can be communicated regarding pathology that was not visible in the image/video clips provided.

Thank you for this referral. If the clinical or image interpretation does not parallel your findings or if I can be of any further assistance please contact me.

Nele Eley, DVM, Dr. med. vet., DipECVDI
European Specialist in Veterinary Diagnostic Imaging, Cert. Radiology,
Senior lecturer University of Giessen, Germany, Veterinary Faculty, Department of Radiology
Nele.Eley@sonopath.com