


**PATIENT PRESENTING CLINICAL SIGNS**

Pabu Nguyen 7 DAY HISTORY OF LEFT SIDED FACIAL SWELLING, EXOPHTHALMOS OF LEFT EYE. SWELLING REDUCED WITH ABX AND NSAID. SEDATED ORAL EXAM REVEALED FOXTAIL LOGGED BETWEEN 209 AND 210. NO OTHER SIGNIFICANT FINDINGS AFTER EXPLORING THAT AREA. SEVERE SWELLING AND TISSUE THICKENING IN ALL OF UPPER LEFT QUADRANT. LARGE POCKET AT CAUDAL END OF 210 ON BUCCAL SIDE.

**SPECIES**

Canine

**COMPUTED TOMOGRAPHIC STUDY OF THE HEAD**
**BREED**

Corgi

Plain and post-contrast studies available for review.

**COMPUTED TOMOGRAPHIC FINDINGS**

Patient has a history of oral foreign material between the triadans 209 and 210.

**SEX**

Neutered Male

Regional soft tissue swelling is seen in the left side of the face as well as in the left masseter region, and the left orbital tissues present mild generalized swelling as well with mild left-sided exophthalmos. Additional foreign material cannot be identified. There is no evidence of osseous abnormality of the alveolar bone between or in the region of the triadans 209 and 210. The dental elements themselves present within normal limits as well.

**AGE**

1 Year

The submandibular and medial retropharyngeal lymph nodes present within normal limits on both sides.

**COMPUTED TOMOGRAPHIC DIAGNOSIS**
**INTERPRETED BY**

Nele Eley (Ondreka),  
 DVM Dr. med. vet.,  
 DipECVDI

- Regional soft tissue swelling within the left masseter, retromolar and orbital regions – compatible with cellulitis.
- No evidence of cavitary lesions or additional foreign material.
- No significant lymph node enlargement.
- No associated osseous changes of the alveolar bone or dental changes.

**HOSPITAL NAME**

Green Dog Dental and  
 Wellness

**INTERPRETATION OF FINDINGS & FURTHER RECOMMENDATIONS**

The CT findings are compatible with regional cellulitis within the left orbita, causing mild left-sided exophthalmos as well as cellulitis in the left side of the face and retromolar soft tissue. Additional foreign material cannot be identified. There is no evidence of an abscess or osseous or dental involvement at this point.

**REFERRING VET**

Dr. Lau

**INVOICE**

44576

**DATE**

8/7/23



**PATIENT**

Pabu Nguyen

**SPECIES**

Canine

**BREED**

Corgi

**SEX**

Neutered Male

**AGE**

1 Year

**INTERPRETED BY**

Nele Eley (Ondreka),  
DVM Dr. med. vet.,  
DipECVDI

**HOSPITAL NAME**

Green Dog Dental and  
Wellness

**REFERRING VET**

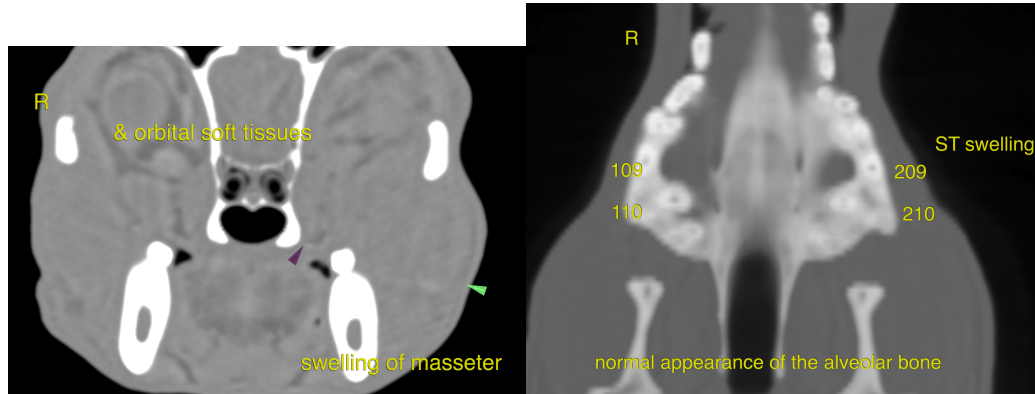
Dr. Lau

**INVOICE**

44576

**DATE**

8/7/23



The information and recommendations provided are based on the images presented by the referring veterinarian. No evaluation can be communicated regarding pathology that was not visible in the image/video clips provided.

Thank you for this referral. If the clinical or image interpretation does not parallel your findings or if I can be of any further assistance please contact me.

**Nele Eley (Ondreka)**, DVM, Dr. med. vet., DipECVDI  
European Specialist in Veterinary Diagnostic Imaging, Cert. Radiology,  
Senior lecturer University of Giessen/Germany, Veterinary Faculty, Department of Radiology.  
Nele.Eley@sonopath.com