
PATIENT PRESENTING CLINICAL SIGNS

Numi Nygren Patient presented for evaluation of dental issues and draining abscess from right side of face. Culture revealed light growth of *Pasteurella multocida*. Has been on PenG and chloramphenicol.

SPECIES COMPUTED TOMOGRAPHIC STUDY OF THE HEAD

Rabbit Plain and post-contrast studies available for review.

COMPUTED TOMOGRAPHIC FINDINGS

BREED Large, cystic expansion of the right maxillary alveolar crest is noted between the triadans 110 and 111. Severe rostral and medial deviation of the triadan 110 with partial resorption of the tooth is seen. The triadan 110 is deviated caudally. The triadans 106-109 are deviated rostrally and asymmetrically positioned. The extent of expansion of the maxillary bone causes severe thinning of the peripheral osseous line of the bones. The cystic expansion blends directly into a cavitory lesion lateral to the right maxilla. The overall size of the two connected cavities is 25 mm in width and 15 mm in height and length each. There appears to be regional dermal thickening and an open connection to the surface emerging from the cavitory lesion.

Rabbit

SEX Spayed Female

AGE The right submandibular and medial retropharyngeal lymph nodes are moderately enlarged.

3 Years The mass effect of the cavitory lesion and maxillary expansion causes a reduction of the right orbital space with exophthalmos.

Mild pointing of the dental crowns of the molar teeth is seen and accentuated in the left quadrants.

INTERPRETED BY

Nele Eley (Ondreka),
 DVM Dr. med. vet.,
 DipECVDI

COMPUTED TOMOGRAPHIC DIAGNOSIS

- Dental abscess with drainage tract formation in the right maxilla emerging from the triadan 110
- Mass effect within the right orbita with exophthalmos
- Right submandibular and medial retropharyngeal lymphadenomegaly

HOSPITAL NAME

Mobile Pet Imaging

INTERPRETATION OF FINDINGS & FURTHER RECOMMENDATIONS
REFERRING VET

Dr. Seraydar

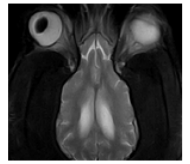
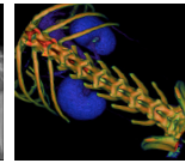
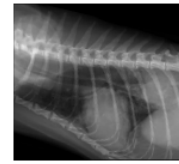
The CT findings are highly suggestive for a dental abscess with regional osteitis and drainage tract formation emerging from the triadan 110. 110 is partially resorbed and severely distorted. Dentigerous cyst and neoplasia are potential but far less likely differential diagnoses. The regional lymphadenomegaly is suggestive for reactive lymphadenitis. A lymphomatous or other infiltrate is unlikely.

INVOICE

44520

DATE

8/7/23



PATIENT

Numi Nygren

SPECIES

Rabbit

BREED

Rabbit

SEX

Spayed Female

AGE

3 Years

INTERPRETED BY

Nele Eley (Ondreka),
DVM Dr. med. vet.,
DipECVDI

The information and recommendations provided are based on the images presented by the referring veterinarian. No evaluation can be communicated regarding pathology that was not visible in the image/video clips provided.

HOSPITAL NAME

Mobile Pet Imaging

Thank you for this referral. If the clinical or image interpretation does not parallel your findings or if I can be of any further assistance please contact me.

REFERRING VET

Dr. Seraydar

Nele Eley (Ondreka), DVM, Dr. med. vet., DipECVDI
European Specialist in Veterinary Diagnostic Imaging, Cert. Radiology,
Senior lecturer University of Giessen/Germany, Veterinary Faculty, Department of Radiology.
Nele.Eley@sonopath.com

INVOICE

44520

DATE

8/7/23

