



PATIENT PRESENTING CLINICAL SIGNS

Ebbi Carson Survey wellness radiographs for any potential abnormalities, P is not clinical for any pathologies.

SPECIES RADIOGRAPHIC STUDY OF THE THORAX & ABDOMEN

Canine Right/left lateral and ventrodorsal views of the thorax and abdomen each totaling 7 images available for review.

BREED RADIOGRAPHIC FINDINGS

Labrador Retriever Mix

Thorax

The surrounding bony structures are within normal limits.

The extrathoracic soft tissues present homogeneous without abnormalities.

SEX

FS

The heart is of normal size and shape and there is no evidence of cardiac chamber or vascular enlargement. The vertebral baseline heart score is 9.9. The pulmonary vasculature is within normal limits.

AGE

4.5 Years

The cranial mediastinum presents the expected soft tissue opacity. The mediastinal width is less than twice the width of the vertebral column at the same level.

The trachea is normal in diameter and presents the anticipated course. The luminal outline of the trachea is smooth.

INTERPRETED BY

Nele Eley, DVM
Dr. med. Vet. DipECVCI

The bronchial tree presents with thin walls and tapers uniformly towards the periphery as expected.

The lung parenchyma presents the expected architecture and opacity. The intrapulmonary vascular branching is seen up to the third order lung vessels.

HOSPITAL NAME

Boca Park Animal Hospital

The diaphragm is well delineated with even surface and the expected mild cranial bulging of the diaphragmatic cupola.

Abdomen

REFERRING VET

Tifanie Silver

The surrounding bony structures are within normal limits.

No abnormalities of the extraabdominal soft tissues are noted. The abdominal wall is smooth and thin.

INVOICE

47083

The serosal detail is maintained throughout the peritoneal and retroperitoneal space.

The liver is appropriate in position, size and presents uniform opacity.

DATE

8-6-21

The splenic head is in the anticipated position and within normal limits for size and opacity. The splenic body and tail are considered normal for position, size, shape and opacity.



PATIENT

Ebbi Carson

Both kidneys are seen and present with normal size, shape, delineation and opacity. The urinary bladder is in its anticipated position. No radiopaque calculi are noted throughout the upper and lower urinary tract.

The stomach is in its anticipated position and presents normal content.

SPECIES

Canine

The small intestinal loops are of even diameter and non-dilated, a small amount of gas is seen within the small intestinal loops and considered within normal limits.

The colon is seen in the expected position and presents with appropriate content.

BREED

Labrador Retriever
Mix

RADIOGRAPHIC DIAGNOSIS

- Radiographically normal thorax & abdomen.

INTERPRETATION OF THE FINDINGS & FURTHER RECOMMENDATIONS

SEX

FS

The radiographic screening of the thoracic and abdominal cavities is within age related normal limits. No structural evidence of cardiovascular or bronchopulmonary pathology is seen. The radiographic presentation of the abdominal viscera is within normal limits. There is no evidence of abdominal mass effects.

AGE

4.5 Years

INTERPRETED BY

Nele Eley, DVM
Dr. med. Vet. DipECVDI

HOSPITAL NAME

Boca Park Animal
Hospital

REFERRING VET

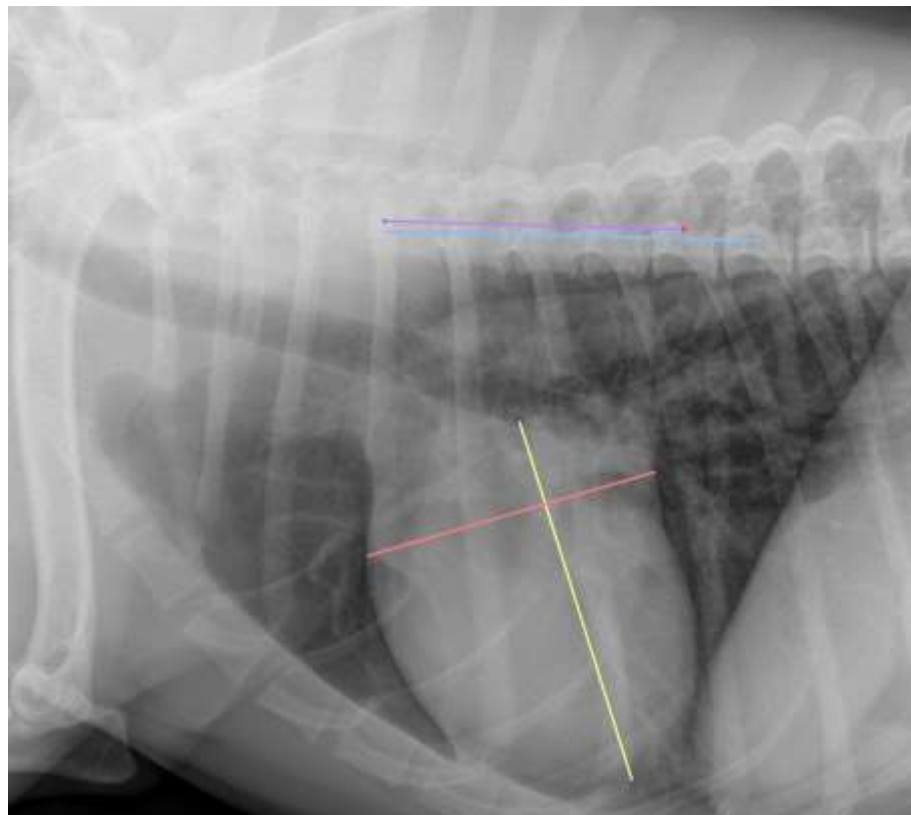
Tifanie Silver

INVOICE

47083

DATE

8-6-21





PATIENT

Ebbi Carson

The information and recommendations provided are based on the images presented by the referring veterinarian. No evaluation can be communicated regarding pathology that was not visible in the image/video clips provided.

Thank you for this referral. If the clinical or image interpretation does not parallel your findings or if I can be of any further assistance please contact me.

SPECIES

Canine

Nele Eley, DVM, Dr. med. vet., DipECVDI
European Specialist in Veterinary Diagnostic Imaging, Cert. Radiology,
Senior lecturer University of Giessen, Germany, Veterinary Faculty, Department of Radiology
Nele.Eley@sonopath.com

BREED

Labrador Retriever
Mix

SEX

FS

AGE

4.5 Years

INTERPRETED BY

Nele Eley, DVM
Dr. med. Vet. DipECVDI

HOSPITAL NAME

Boca Park Animal
Hospital

REFERRING VET

Tifanie Silver

INVOICE

47083

DATE

8-6-21