



PATIENT

Hank Mann

PRESENTING CLINICAL SIGNS

Very active dog with a history of bilateral forelimb lameness causing stiffness and difficulty rising with rest following exercise. High speed sharp turns will also elicit a lameness that lasts up to an hour. Radiographs demonstrated mild osteophytic change of the caudal humeral head and sclerosis of the bicipital groove bilaterally. On examination, there is pain on shoulder flexion, particularly with a concurrent extended elbow.

SPECIES

Canine

ULTRASONOGRAPHIC FINDINGS

BREED

Left Shoulder

German Shorthaired Pointer

The left supraspinatus tendon measures 7.5mm in maximum thickness. Multiple echogenic foci are seen within the supraspinatus tendon. One 2mm sized partially shadowing lesion is seen in the distal and medial part close to the biceps tendon. The transverse ligament presents moderate thickening. Mild thickening of the bicipital synovium is seen. There is a mild amount of smooth new bone within the intertubercular groove. Mild to moderate effusion is noted within the bicipital tendon sheath.

SEX

MN

Right Shoulder

AGE

6 Years

8mm thickness of the supraspinatus tendon is noted. Moderate remodeling with multiple partially shadowing echogenic foci of the supraspinatus tendon are seen, especially the distal and medial part of the tendon is ill-defined. Transverse thickening and mild biceps impingement are noted. The biceps tendon sheath presents moderate thickening. Two small core lesions are seen level with the proximal aspect of the intertubercular groove within the biceps tendon both of which measuring less than 10% of the cross sectional area at the same level. Tendon margins are slightly ill-defined. A moderate amount of new bone is seen within the intertubercular groove of the biceps tendon.

INTERPRETED BY

Nele Eley, DVM
Dr. med. Vet. DipECVDI

ULTRASONOGRAPHIC DIAGNOSIS

HOSPITAL NAME

Points East West
Veterinary Services

- Moderate right supraspinatus tendinopathy with biceps impingement and moderate chronic biceps tenosynovitis with two small core lesions.
- Mild left supraspinatus tendinopathy with biceps impingement and mild chronic biceps tenosynovitis.

REFERRING VET

David Lane

INTERPRETATION OF THE FINDINGS & FURTHER RECOMMENDATIONS

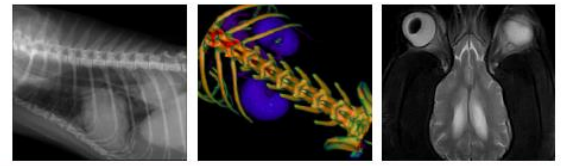
Supraspinatus tendinopathy with biceps impingement is noted in both shoulders. The bicipital tendon sheaths of both shoulders presents signs of chronic biceps tenosynovitis. The changes are moderate if not severe on the right side and mild to moderate on the left side. The right biceps tendon presents two small core lesions while the changes are limited to the bicipital tendon sheath and intertubercular groove on the left side, the tendon itself is, at this point at least, ultrasonographically unaffected in the left shoulder.

INVOICE

53302

DATE

8-5-22



PATIENT

Hank Mann

SPECIES

Canine

BREED

German Shorthaired
Pointer

SEX

MN

AGE

6 Years

INTERPRETED BY

Nele Eley, DVM
Dr. med. Vet. DipECVDI

HOSPITAL NAME

Points East West
Veterinary Services

REFERRING VET

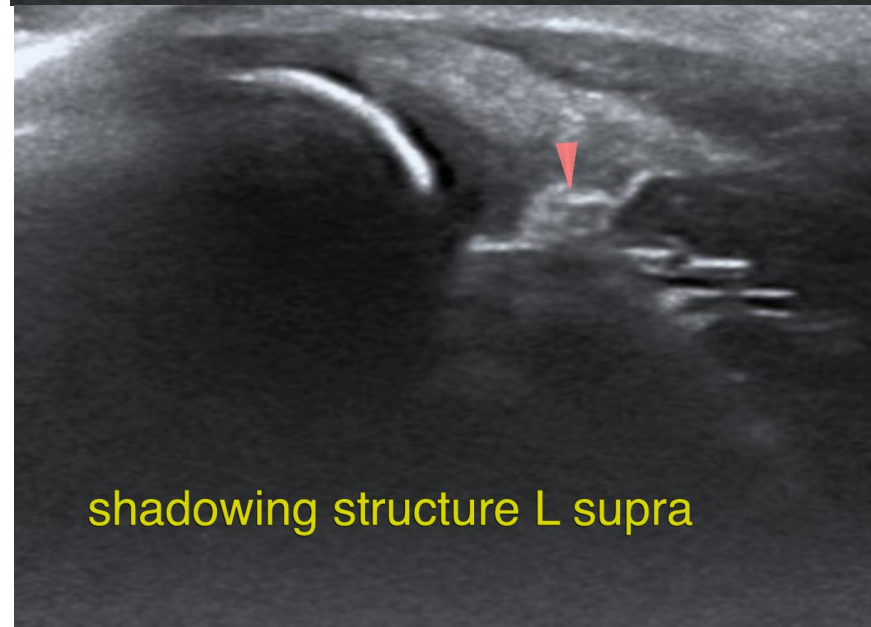
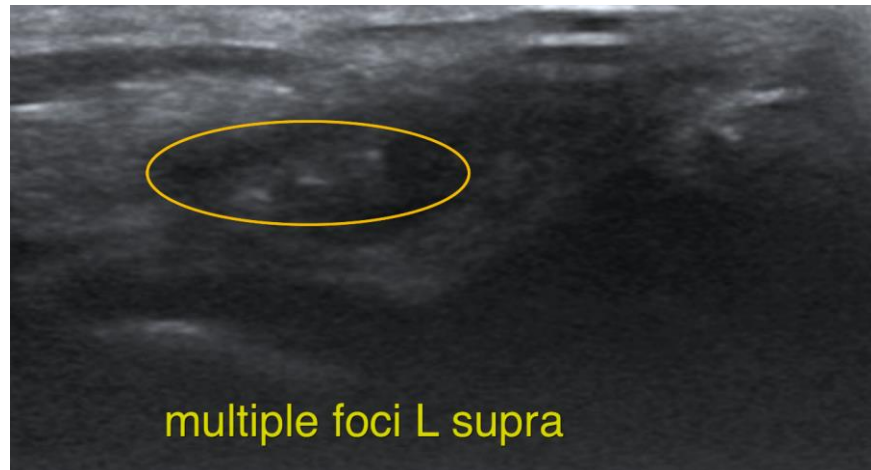
David Lane

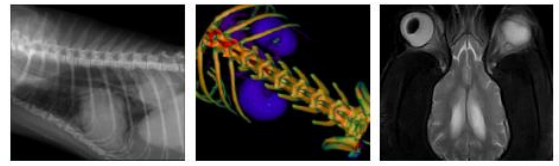
INVOICE

53302

DATE

8-5-22





PATIENT

Hank Mann

SPECIES

Canine

BREED

German Shorthaired
Pointer

SEX

MN

AGE

6 Years

INTERPRETED BY

Nele Eley, DVM
Dr. med. Vet. DipECVDI

HOSPITAL NAME

Points East West
Veterinary Services

REFERRING VET

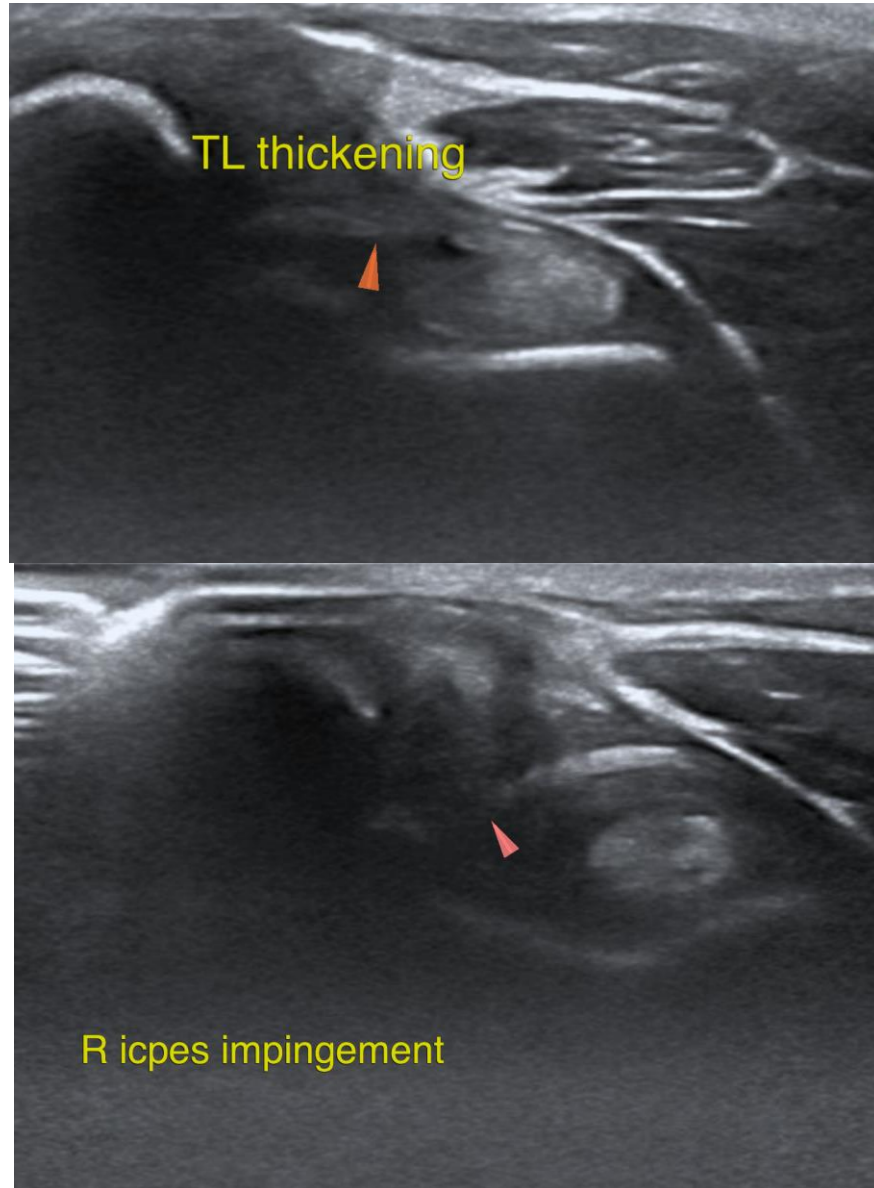
David Lane

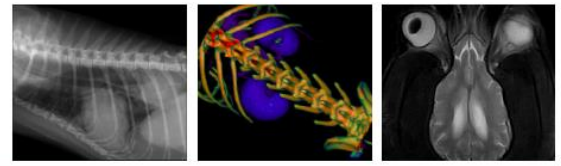
INVOICE

53302

DATE

8-5-22





PATIENT

Hank Mann

SPECIES

Canine

BREED

German Shorthaired
Pointer

SEX

MN

AGE

6 Years

INTERPRETED BY

Nele Eley, DVM
Dr. med. Vet. DipECVDI

HOSPITAL NAME

Points East West
Veterinary Services

REFERRING VET

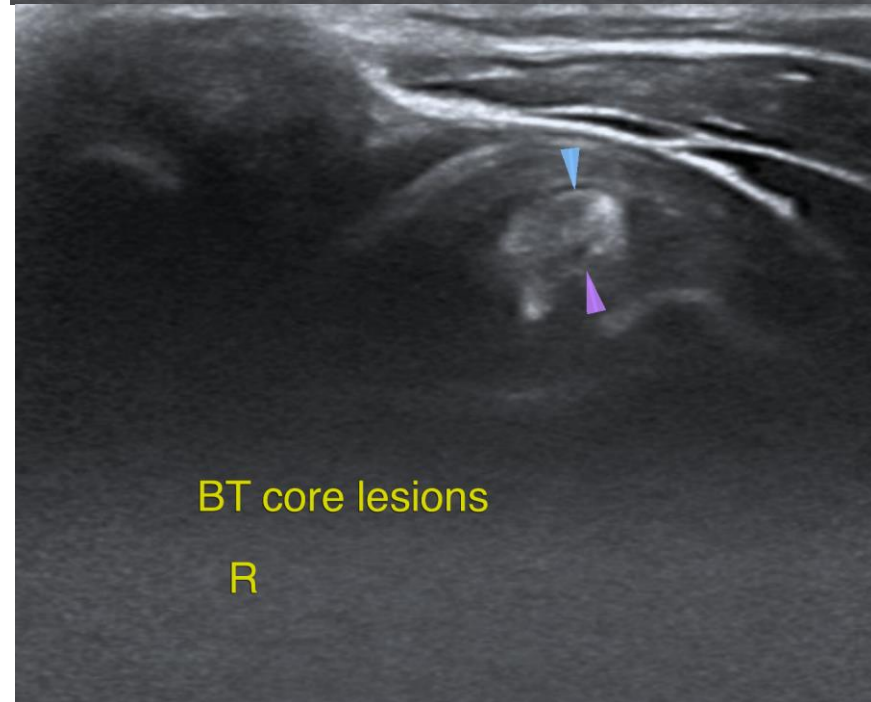
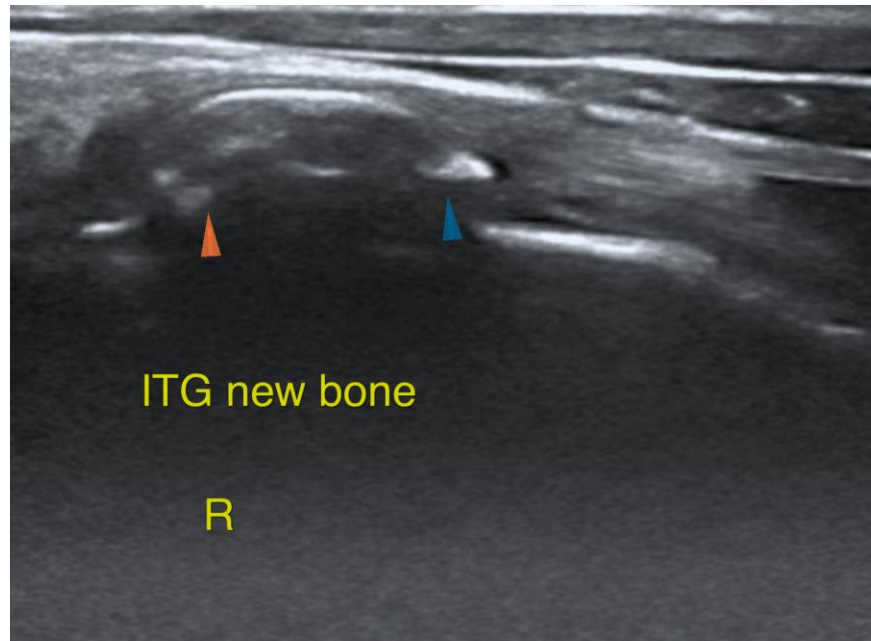
David Lane

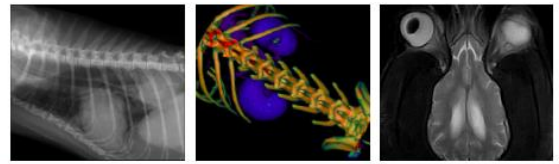
INVOICE

53302

DATE

8-5-22





PATIENT

Hank Mann

The information and recommendations provided are based on the images presented by the referring veterinarian/sonographer. No evaluation can be communicated regarding pathology that was not visible in the image/video clips provided.

Thank you for this referral. If the clinical or image interpretation does not parallel your findings or if I can be of any further assistance please contact me.

SPECIES

Canine

Nele Eley, DVM, Dr. med. vet., DipECVDI
European Specialist in Veterinary Diagnostic Imaging, Cert. Radiology,
Senior lecturer University of Giessen, Germany, Veterinary Faculty, Department of Radiology
Nele.Eley@sonopath.com

BREED

German Shorthaired
Pointer

SEX

MN

AGE

6 Years

INTERPRETED BY

Nele Eley, DVM
Dr. med. Vet. DipECVDI

HOSPITAL NAME

Points East West
Veterinary Services

REFERRING VET

David Lane

INVOICE

53302

DATE

8-5-22