



PATIENT

Toby Hall

PRESENTING CLINICAL SIGNS

coughing , hacking and sneezing for few weeks

SPECIES

Feline

RADIOGRAPHIC STUDY OF THE THORAX & NECK

Right/left lateral and dorsoventral views totaling 3 images available for review.

RADIOGRAPHIC FINDINGS

BREED

DSH

No abnormality of the tympanic bullae is seen.

Age related periarticular bone remodeling of the elbows is noted.

Course and width of the trachea are considered within normal limits.

SEX

Male Neuter

The ribcage is expanded. The lungs are deeply inflated with wide lumbodiaphragmatic angles and relatively flat diaphragmatic cupola. A moderate generalized bronchial lung pattern is noted and evenly distributed throughout the lung.

AGE

13 Years

The cardiac silhouette presents within normal limit. Age related redundancy of the aortic arch is seen.

There is no evidence of abnormal mediastinal widening.

INTERPRETED BY

Nele Eley, DVM
Dr. med. Vet. DipECVDI

RADIOGRAPHIC DIAGNOSIS

- Generalized bronchial lung pattern with air trapping.

INTERPRETATION OF THE FINDINGS & FURTHER RECOMMENDATIONS

The radiographic findings suggest presence of lower airway disease with air trapping. Allergic lower airway syndrome is the most likely underlying cause of the radiographic changes. However, infectious bronchitis such as viral, bacterial, and less likely parasitic, or protozoal cannot be ruled out entirely. Consider a clinical trial of treatment for feline asthma versus further definition by means of airway endoscopy with airway sampling.

HOSPITAL NAME

St. Catherine's Animal
Hospital

REFERRING VET

Dr. Boctor

INVOICE

53282

DATE

8-4-22



PATIENT

Toby Hall

SPECIES

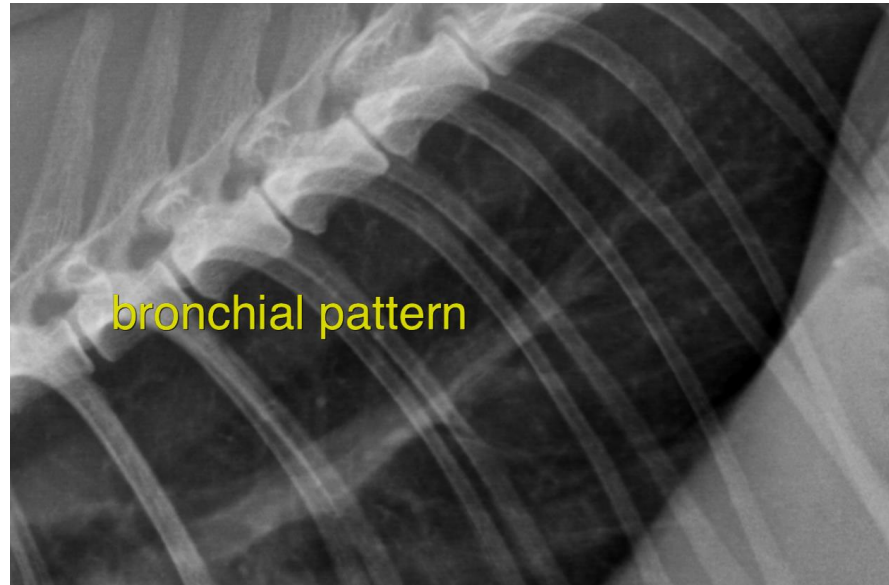
Feline

BREED

DSH

SEX

Male Neuter



AGE

13 Years

INTERPRETED BY

Nele Eley, DVM
Dr. med. Vet. DipECVDI

HOSPITAL NAME

St. Catherine's Animal
Hospital

REFERRING VET

Dr. Boctor

INVOICE

53282

DATE

8-4-22

The information and recommendations provided are based on the images presented by the referring veterinarian/sonographer. No evaluation can be communicated regarding pathology that was not visible in the image/video clips provided.

Thank you for this referral. If the clinical or image interpretation does not parallel your findings or if I can be of any further assistance please contact me.

Nele Eley, DVM, Dr. med. vet., DipECVDI
European Specialist in Veterinary Diagnostic Imaging, Cert. Radiology,
Senior lecturer University of Giessen, Germany, Veterinary Faculty, Department of Radiology
Nele.Eley@sonopath.com