

**PATIENT**

Olga Jantos

PRESENTING CLINICAL SIGNS

acute left forelimb lameness July 2022

SPECIES

Canine

CT STUDY OF THE FRONT LIMBS & MRI STUDY OF THE LEFT SHOULDER

Plain study in bone and soft tissue windows from the elbows through the paws and T2-proton density fat saturated and T1-weighted images of the left shoulder available for review.

COMPUTED TOMOGRAPHIC FINDINGS**Front Limbs**

The elbow, carpal, metacarpophalangeal, and phalangeal joints of both front limbs present within normal limits. No evidence of osseous or articular injury is seen. There is no evidence of elbow dysplasia.

BREED

Labrador Retriever

SEX

FS

Mild generalized atrophy of the left front limb musculature is noted.

AGE

5 Years

Part of the right shoulder is included in the study and small mineralized bodies are seen within the right supraspinatus tendon close to the greater humeral tubercle.

MAGNETIC RESONANCE IMAGING FINDINGS**Left Shoulder**

Moderate effusion is seen within the left shoulder joint and left bicipital tendon sheath. There is a focal hyperintense signal alteration within the distal aspect of the left biceps tendon close to the musculotendinous junction level.

INTERPRETED BYNele Eley, DVM
Dr. med. Vet. DipECVDI

Mild thickening, ill-defined margins, and increased signal intensity of the medial glenohumeral ligament and subscapularis tendon are noted.

HOSPITAL NAMEAnimal Health
Partners**IMAGING DIAGNOSIS**

- Left biceps tendon injury suggesting presence of a core lesion close to the musculotendinous junction, medial compartment injury involving the glenohumeral ligament and subscapularis, left shoulder effusion and bicipital tenosynovitis.
- Mineralizing right supraspinatus tendinopathy - likely incidental.
- Mild disuse atrophy of the left front limb musculature.

REFERRING VET

Dr. Debbie Reynolds

INTERPRETATION OF THE FINDINGS & FURTHER RECOMMENDATIONS**INVOICE**

53281

The findings suggest presence of concurrent biceps and medial joint compartment injury in the left shoulder. The signal alteration within the biceps tendon close to the musculotendinous junction suggests presence of a core lesion. The findings of the medial glenohumeral ligament and subscapularis suggest presence of concurrent medial compartment injury with potential for medial instability. Medial abduction angles should be checked in this patient.

DATE

8-4-22



PATIENT

Olga Jantos

SPECIES

Canine

BREED

Labrador Retriever

SEX

FS

AGE

5 Years

INTERPRETED BY

Nele Eley, DVM
Dr. med. Vet. DipECVDI

HOSPITAL NAME

Animal Health
Partners

REFERRING VET

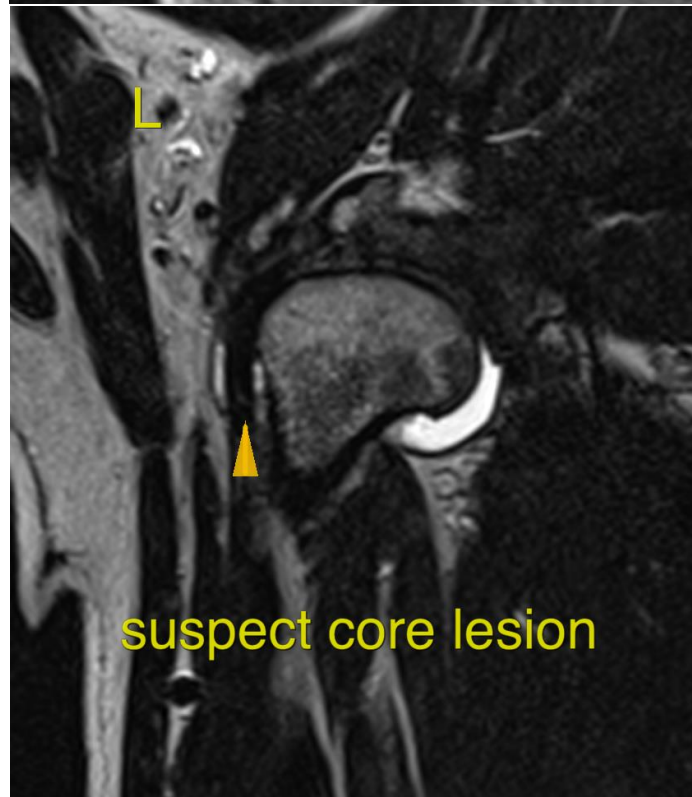
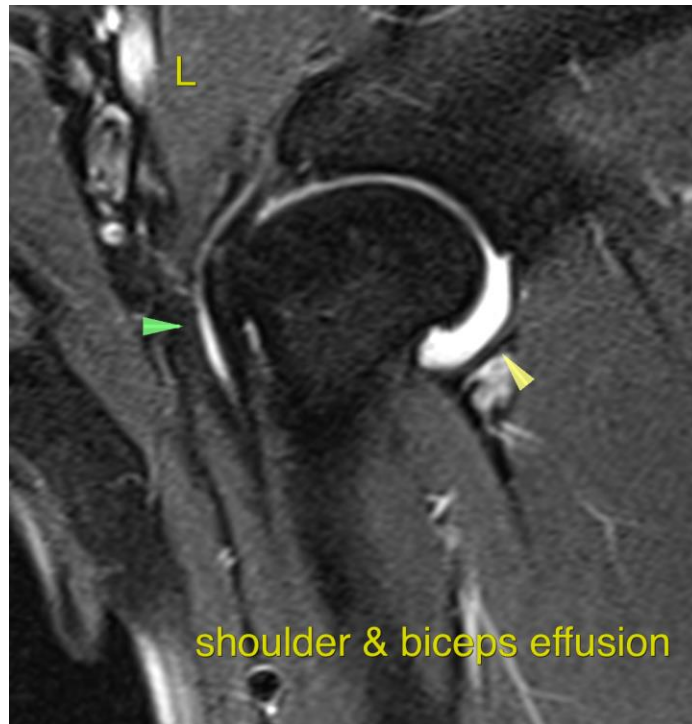
Dr. Debbie Reynolds

INVOICE

53281

DATE

8-4-22





PATIENT

Olga Jantos

SPECIES

Canine

BREED

Labrador Retriever

SEX

FS

AGE

5 Years

INTERPRETED BY

Nele Eley, DVM
Dr. med. Vet. DipECVDI

HOSPITAL NAME

Animal Health
Partners

REFERRING VET

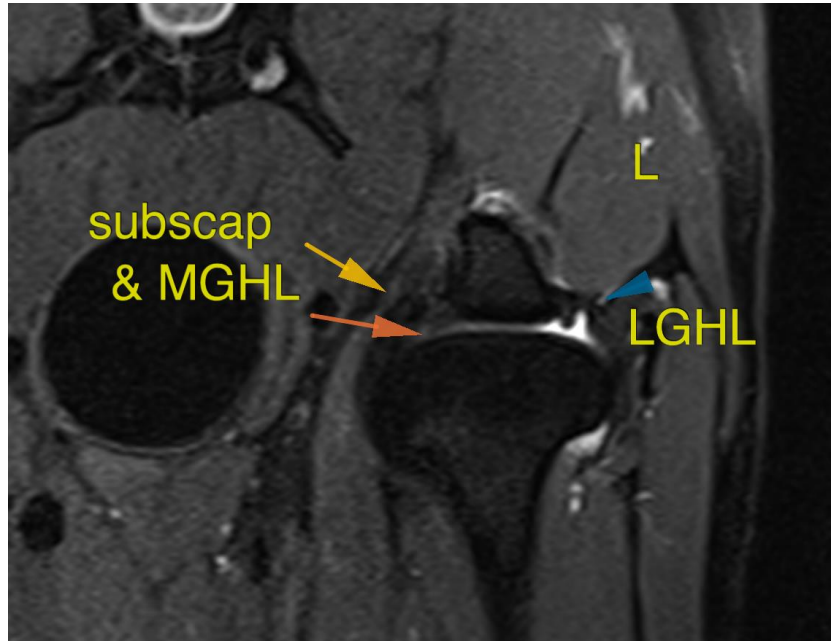
Dr. Debbie Reynolds

INVOICE

53281

DATE

8-4-22



The information and recommendations provided are based on the images presented by the referring veterinarian/sonographer. No evaluation can be communicated regarding pathology that was not visible in the image/video clips provided.

Thank you for this referral. If the clinical or image interpretation does not parallel your findings or if I can be of any further assistance please contact me.

Nele Eley, DVM, Dr. med. vet., DipECVDI
European Specialist in Veterinary Diagnostic Imaging, Cert. Radiology,
Senior lecturer University of Giessen, Germany, Veterinary Faculty, Department of Radiology
Nele.Eley@sonopath.com