



**PATIENT PRESENTING CLINICAL SIGNS**

**Ensign Catt**  
**SPECIES** Canine  
**BREED** Ibizan Hound

History rupture of the left gastrocnemius and common calcaneal tendon of the deep tendon first diagnosed in July 2021. A recheck US after surgery was performed in October 2021 showed non-healing 3 months after surgery. The patient has since had repeat surgery and external fixation, and has been undergoing rehab. This is a recheck US to assess healing. Images of the Achilles tendon and the gastrocnemius muscle are sent for evaluation. Clinically the patient is doing better.

Abnormal PE/Chem/CBC/UA Results: 1. assess post-surgical healing of the left Achilles tendon 2. subtle swelling in the left gastrocnemius muscle just proximal to the musculotendinous junction

**ULTRASONOGRAPHIC FINDINGS**

**Left Achilles Tendon**

**SEX** Male  
 Patient has a history of repeated surgical repair of a rupture of the deep left achilles tendon with the latest surgery in October 2021.

Suture material is seen in the area of prior injury.

**AGE** 7 Years  
 The area of prior injury is partially filled with fibers of short and medium length. Remnants of hypoechoic tissue are seen in the center of the injured area.

Moderate generalized swelling of the deep achilles tendon is noted.

**INTERPRETED BY** Nele Eley, DVM  
 Dr. med. Vet. DipECVDI  
 The superficial digital flexor tendon is continuous and well delineated.

Mild generalized dermal thickening is noted.

There is mild osseous remodeling of the calcaneal tubercle.

**HOSPITAL NAME** Mountain Vista Veterinary Hospital  
 An area of decreased echogenicity with partial loss of echoarchitecture is seen proximal to the musculotendinous junction of the gastrocnemius muscle.

**ULTRASONOGRAPHIC DIAGNOSIS**

- Suspect delayed healing after left deep achilles tendon injury with surgical repair.
- Partial rupture of the left gastrocnemius in the musculotendinous junction area.

**REFERRING VET** Dr. Jacquie Pankatz  
**INTERPRETATION OF THE FINDINGS & FURTHER RECOMMENDATIONS**

**INVOICE** 53272  
 The ultrasonographic findings suggest delayed healing of the left deep achilles tendon injury which is not necessarily unexpected considering the patient history. However, more than 6 months after the surgical repair, the usual course of healing presents with uniformly oriented fibers of medium length representing scar tissue in the tendinous defect.

**DATE** 8-4-22  
 Note the presence of a small partial rupture of the left gastrocnemius immediately proximal to the musculotendinous junction level which is not uncommon in patients with prior achilles tendon injury.



**PATIENT**

Continuation of rehab/physical therapy and careful resumption of exercise are recommended.

Ensign Catt

**SPECIES**

Canine

**BREED**

Ibizan Hound

**SEX**

Male

**AGE**

7 Years

**INTERPRETED BY**

Nele Eley, DVM  
Dr. med. Vet. DipECVDI

**HOSPITAL NAME**

Mountain Vista  
Veterinary Hospital

**REFERRING VET**

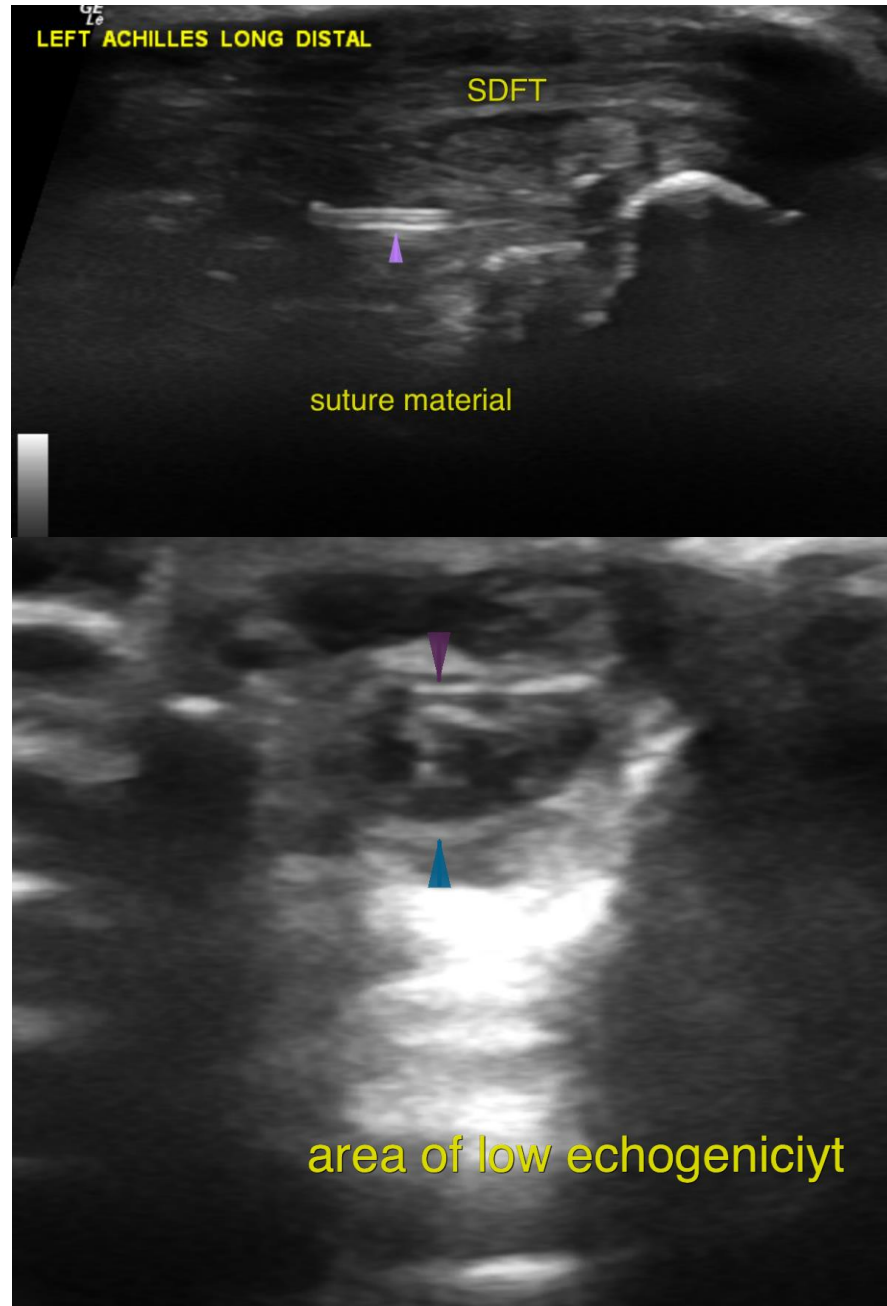
Dr. Jacquie Pankatz

**INVOICE**

53272

**DATE**

8-4-22





**PATIENT**

Ensign Catt

**SPECIES**

Canine

**BREED**

Ibizan Hound

**SEX**

Male

**AGE**

7 Years

**INTERPRETED BY**

Nele Eley, DVM  
Dr. med. Vet. DipECVDI

**HOSPITAL NAME**

Mountain Vista  
Veterinary Hospital

**REFERRING VET**

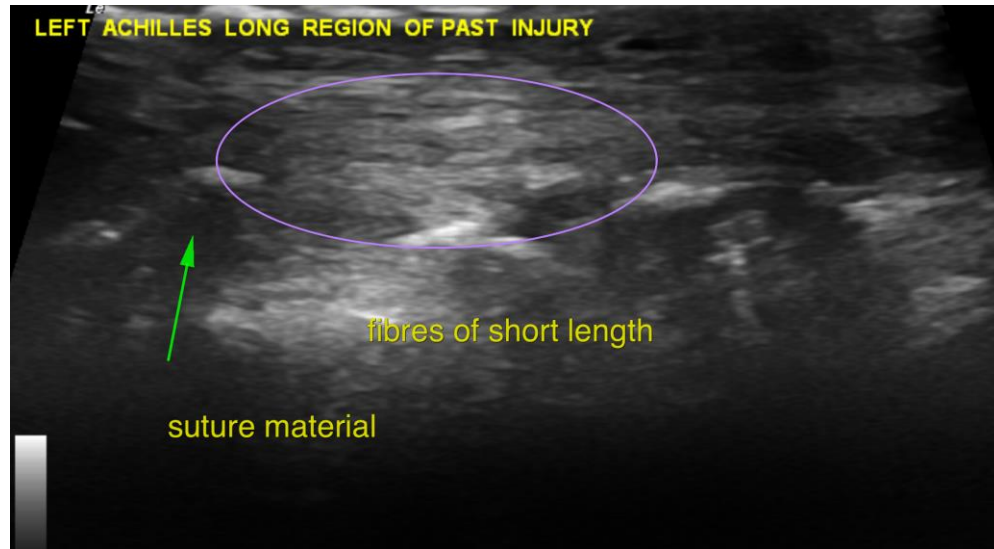
Dr. Jacquie Pankatz

**INVOICE**

53272

**DATE**

8-4-22



The information and recommendations provided are based on the images presented by the referring veterinarian/sonographer. No evaluation can be communicated regarding pathology that was not visible in the image/video clips provided.

Thank you for this referral. If the clinical or image interpretation does not parallel your findings or if I can be of any further assistance please contact me.

**Nele Eley**, DVM, Dr. med. vet., DipECVDI  
European Specialist in Veterinary Diagnostic Imaging, Cert. Radiology,  
Senior lecturer University of Giessen, Germany, Veterinary Faculty, Department of Radiology  
Nele.Eley@sonopath.com