

**PATIENT**

Drake Hardy

PRESENTING CLINICAL SIGNS

Acutely lame at home 4 nights ago after lying down to rest. The lameness has been getting worse. He is normal otherwise.

Abnormal PE/Chem/CBC/UA Results: Mild muscle atrophy of LEFT Front. 3/5 RIGHT Front lame. No pain or inflammation isolated. No cervical or other pain or inflammation isolated.

SPECIES

Canine

RADIOGRAPHIC STUDY OF THE FRONT LIMBS

Mediolateral (flexed and extended) and craniocaudal views of both shoulders, elbows, carpi, and front paws totaling 23 images available for review.

BREED

Labrador Retriever

RADIOGRAPHIC FINDINGS

Blurring and decreased opacity of the cranioproximal part of the medial coronoid processes is seen in both elbows. There is subtrochlear notch sclerosis of the ulna and a mild radioulnar step formation. Mild osteophytes are seen on the proximal contour of the anconeal processes, lateral humeral epicondyles, and cranial margin of the radial heads.

SEX

MN

The shoulders, carpi, and front paws present within age related normal limits.

AGE

9 Years, 4 Months

RADIOGRAPHIC DIAGNOSIS

- Bilateral medial coronoid pathology with mild to moderate secondary osteoarthritis.
- Normal radiographic presentation of the shoulders, carpi, and front paws.

INTERPRETED BY

Nele Eley, DVM
Dr. med. Vet. DipECVDI

INTERPRETATION OF THE FINDINGS & FURTHER RECOMMENDATIONS

The only structural abnormalities noted are in the front limbs are located in the elbows. There is radiographic evidence of medial coronoid pathology with mild to moderate secondary osteoarthritic changes in both elbows. The changes are fairly symmetric between the right and left front limb. Correlation with the clinical findings is recommended and CT and arthroscopy of the elbows could be pursued should the patient's clinical signs and lameness be attributable to the elbow changes.

HOSPITAL NAME

Elizabeth Animal
Hospital

REFERRING VET

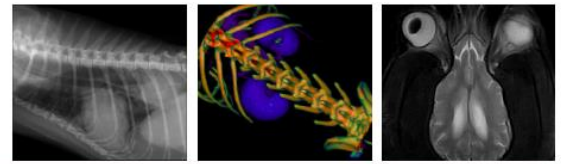
Leon Anderson, DVM

INVOICE

53284

DATE

8-4-22



PATIENT

Drake Hardy

SPECIES

Canine

BREED

Labrador Retriever

SEX

MN

AGE

9 Years, 4 Months

INTERPRETED BY

Nele Eley, DVM
Dr. med. Vet. DipECVDI

HOSPITAL NAME

Elizabeth Animal
Hospital

REFERRING VET

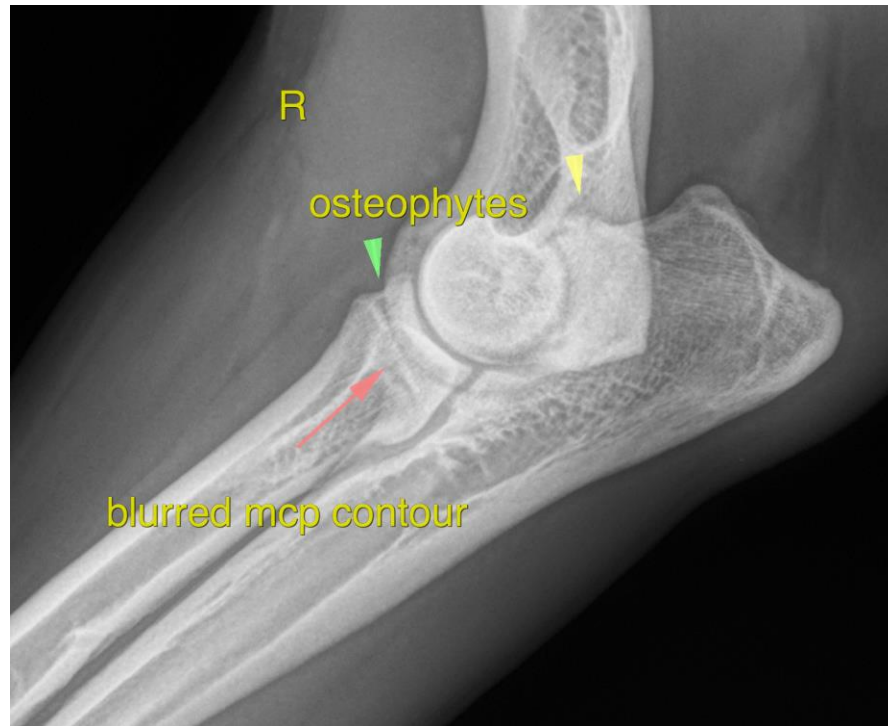
Leon Anderson, DVM

INVOICE

53284

DATE

8-4-22



The information and recommendations provided are based on the images presented by the referring veterinarian/sonographer. No evaluation can be communicated regarding pathology that was not visible in the image/video clips provided.

Thank you for this referral. If the clinical or image interpretation does not parallel your findings or if I can be of any further assistance please contact me.

Nele Eley, DVM, Dr. med. vet., DipECVDI
European Specialist in Veterinary Diagnostic Imaging, Cert. Radiology,
Senior lecturer University of Giessen, Germany, Veterinary Faculty, Department of Radiology
Nele.Eley@sonopath.com