

PATIENT

Macy Latimer

PRESENTING CLINICAL SIGNS

'Ran into another dog' over the weekend per owner and after that was non-weight bearing on her right hind.

Abnormal PE/Chem/CBC/UA Results: On presentation no CP's in hind legs, no use of hind legs, still has deep pain response

SPECIES

Canine

COMPUTED TOMOGRAPHIC STUDY OF THE SPINE

Plain and myelogram with lumbar puncture available for review.

BREED

Chihuahua Mix

COMPUTED TOMOGRAPHIC FINDINGS

Reduced intervertebral disc space width is seen between T12 and T13. There appears to be an isoattenuating disc hernia in the ventral and right epidural space at T12/13. The dorsal and lateral subarachnoid contrast spaces are reduced in width level with T12 and T13. It is somewhat harder to assess the ventral subarachnoid contrast space as there is significant epidural leakage especially in the ventral compartment. However, the epidural contrast is deviated and reduced in the right ventral extradural space.

SEX

Female Spayed

COMPUTED TOMOGRAPHIC DIAGNOSIS

- Suspect isoattenuating intervertebral disc extrusion with right ventral spinal cord compression and spinal cord swelling at T12/13.

INTERPRETED BY

Nele Eley, DVM
Dr. med. Vet. DipECVDI

INTERPRETATION OF THE FINDINGS & FURTHER RECOMMENDATIONS

The CT findings strongly suggest presence of an acute isoattenuating intervertebral disc extrusion at T12/13. The extruded disc material is isoattenuating to the dural tube and spinal cord which makes it hard to delineate. However, mild to moderate compression of the spinal cord appear to be present at T12/13 from a ventral and right aspect.

HOSPITAL NAME

Catskill Veterinary
Services, PLLC

REFERRING VET

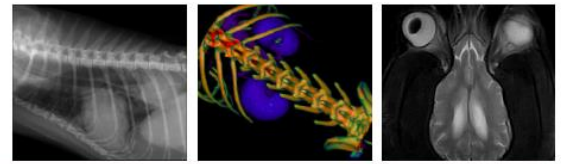
Dr. Daniela Carbone

INVOICE

53878

DATE

8-31-22



PATIENT

Macy Latimer

SPECIES

Canine

BREED

Chihuahua Mix

SEX

Female Spayed

AGE

9 Years

INTERPRETED BY

Nele Eley, DVM
Dr. med. Vet. DipECVDI

HOSPITAL NAME

Catskill Veterinary
Services, PLLC

REFERRING VET

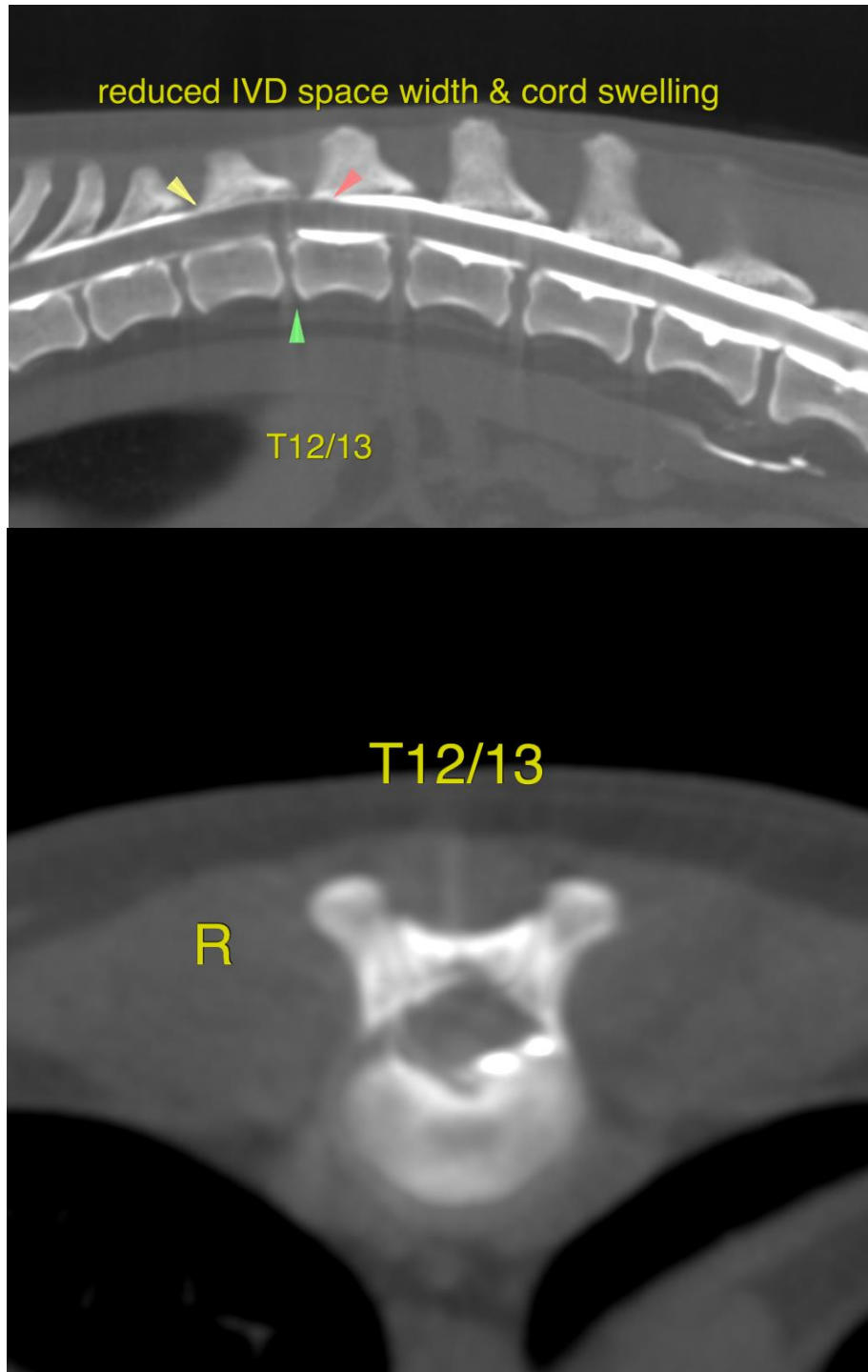
Dr. Daniela Carbone

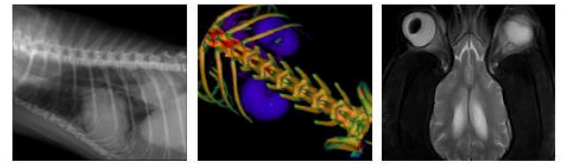
INVOICE

53878

DATE

8-31-22





PATIENT

Macy Latimer

The information and recommendations provided are based on the images presented by the referring veterinarian/sonographer. No evaluation can be communicated regarding pathology that was not visible in the image/video clips provided.

Thank you for this referral. If the clinical or image interpretation does not parallel your findings or if I can be of any further assistance please contact me.

SPECIES

Canine

Nele Eley, DVM, Dr. med. vet., DipECVDI
European Specialist in Veterinary Diagnostic Imaging, Cert. Radiology,
Senior lecturer University of Giessen, Germany, Veterinary Faculty, Department of Radiology
Nele.Eley@sonopath.com

BREED

Chihuahua Mix

SEX

Female Spayed

AGE

9 Years

INTERPRETED BY

Nele Eley, DVM
Dr. med. Vet. DipECVDI

HOSPITAL NAME

Catskill Veterinary
Services, PLLC

REFERRING VET

Dr. Daniela Carbone

INVOICE

53878

DATE

8-31-22