



PATIENT

Jackson Blace

PRESENTING CLINICAL SIGNS

Was palying with another dog and yelped out and was non weight bearing n the left rear leg
Abnormal PE/Chem/CBC/UA Results: Very unstable knee, Positive CTT and Cr drawer sign

SPECIES

Canine

ULTRASONOGRAPHIC FINDINGS

Left Stifle

A large amount of anechoic effusion is present in the supra- and infra- patellar recesses of the left stifle joint. Moderate swelling of the stifle joint synovium is seen.

BREED

Mixed

The cranial cruciate ligament presents as a rather hypoechoic long stump of fibers at the intercondylar eminence of the tibia surrounded by a thin hypoechoic halo.

SEX

MN

The lateral meniscus is in situ, well delineated, and of normal uniform internal echoarchitecture. The medial meniscus is well aligned with the bone surfaces in situ, well delineated, and of normal uniform internal echoarchitecture.

ULTRASONOGRAPHIC DIAGNOSIS

- Full rupture of the left cranial cruciate ligament with no evidence of concurrent meniscopathy.
- Moderate synovialitis and severe effusion of the left stifle joint.

AGE

10 Years, 3 Months

INTERPRETATION OF THE FINDINGS & FURTHER RECOMMENDATIONS

The ultrasonographic findings are compatible with severe effusion and synovialitis as well as rather acute and full rupture of the cranial cruciate ligament. Surgical intervention is indicated in order to address the biomechanical instability and prevent further damage to the articular structures.

INTERPRETED BY

Nele Eley, DVM
Dr. med. Vet. DipECVDI

HOSPITAL NAME

Westview Veterinary
Hospital

REFERRING VET

Dr. Brian Barnes

INVOICE

53856

DATE

8-31-22



PATIENT

Jackson Blace

SPECIES

Canine

BREED

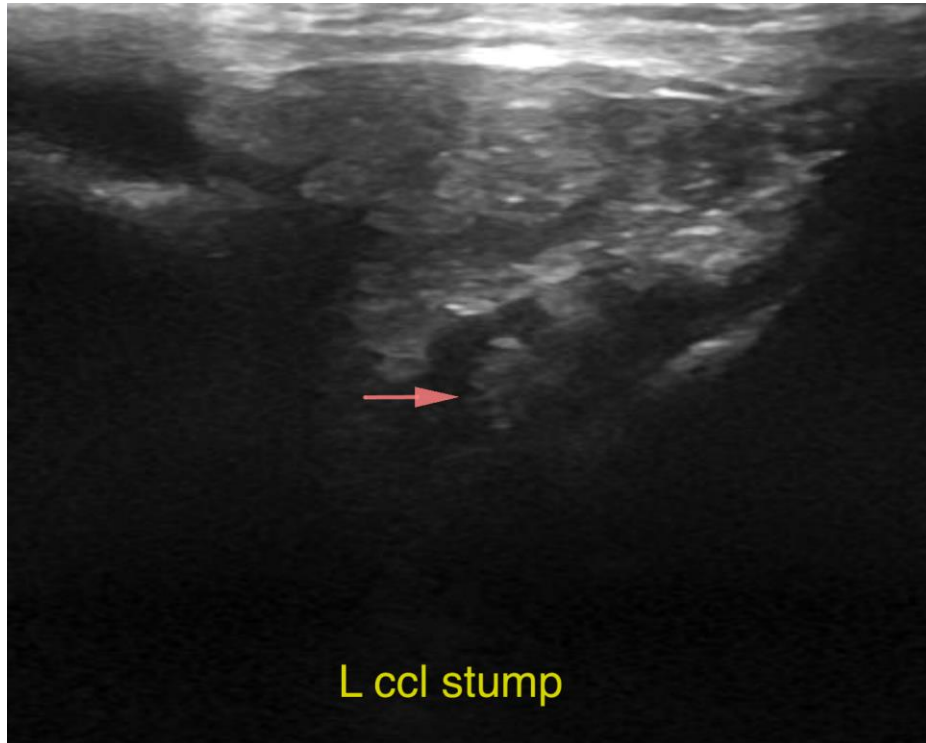
Mixed

SEX

MN

AGE

10 Years, 3 Months



INTERPRETED BY

Nele Eley, DVM
Dr. med. Vet. DipECVDI

The information and recommendations provided are based on the images presented by the referring veterinarian/sonographer. No evaluation can be communicated regarding pathology that was not visible in the image/video clips provided.

Thank you for this referral. If the clinical or image interpretation does not parallel your findings or if I can be of any further assistance please contact me.

HOSPITAL NAME

Westview Veterinary
Hospital

Nele Eley, DVM, Dr. med. vet., DipECVDI
European Specialist in Veterinary Diagnostic Imaging, Cert. Radiology,
Senior lecturer University of Giessen, Germany, Veterinary Faculty, Department of Radiology
Nele.Eley@sonopath.com

REFERRING VET

Dr. Brian Barnes

INVOICE

53856

DATE

8-31-22