



PATIENT

Chico Louigene

PRESENTING CLINICAL SIGNS

history of bilateral mpl - having some difficulty jumping up on furniture
Abnormal PE/Chem/CBC/UA Results: p sedated for rads - had dental prophy as well.

SPECIES

Canine

RADIOGRAPHIC STUDY OF THE STIFLES

Mediolateral and craniocaudal views of both stifles totaling 4 images available for review.

BREED

Mixed Breed

RADIOGRAPHIC FINDINGS

No significant articular swelling of the stifle joints is noted.

There is mild apical remodeling of the patellae in both stifle joints. The patellae however are in situ on all available images.

SEX

Male

The muscle volume of both hind limbs appears to be symmetric and adequate.

RADIOGRAPHIC DIAGNOSIS

- Mild apical osseous remodeling of the patellae – otherwise, normal radiographic presentation of the stifle joints.

AGE

6 Years

INTERPRETATION OF THE FINDINGS & FURTHER RECOMMENDATIONS

The patellae are in situ at the time of the radiographic examination. The apical remodeling may be due to intermittent patella luxation, however, anatomic variant is a potential as well. Grade 1 or 2 patella luxation cannot be ruled out. However, the clinical significance is uncertain in absence of significant osteoarthritic changes. Clinical correlation is required.

INTERPRETED BY

Nele Eley, DVM
Dr. med. Vet. DipECVDI

HOSPITAL NAME

The Pet Hospital of
Stratford

REFERRING VET

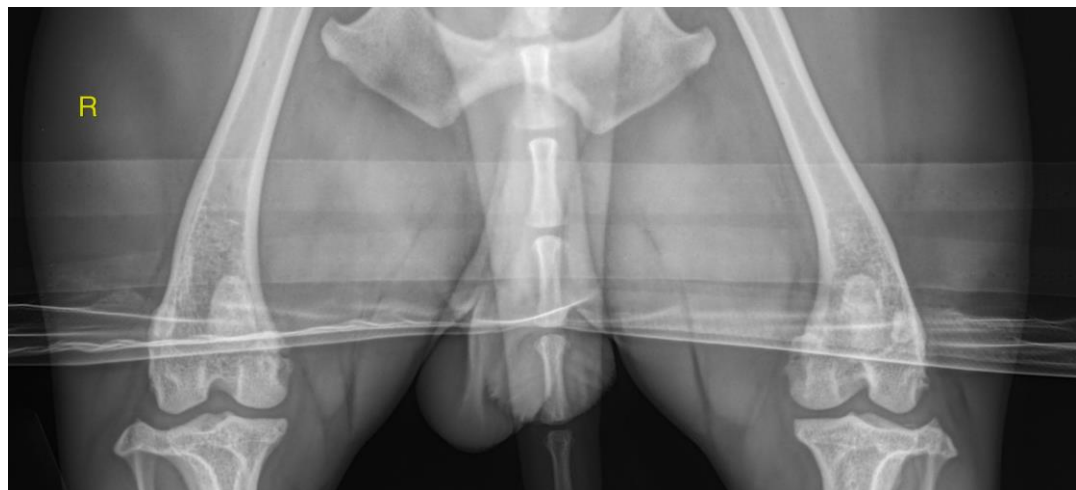
Dr Robert Bashkin

INVOICE

53880

DATE

8-31-22





PATIENT

Chico Louigene

The information and recommendations provided are based on the images presented by the referring veterinarian/sonographer. No evaluation can be communicated regarding pathology that was not visible in the image/video clips provided.

Thank you for this referral. If the clinical or image interpretation does not parallel your findings or if I can be of any further assistance please contact me.

SPECIES

Canine

Nele Eley, DVM, Dr. med. vet., DipECVDI
European Specialist in Veterinary Diagnostic Imaging, Cert. Radiology,
Senior lecturer University of Giessen, Germany, Veterinary Faculty, Department of Radiology
Nele.Eley@sonopath.com

BREED

Mixed Breed

SEX

Male

AGE

6 Years

INTERPRETED BY

Nele Eley, DVM
Dr. med. Vet. DipECVDI

HOSPITAL NAME

The Pet Hospital of
Stratford

REFERRING VET

Dr Robert Bashkin

INVOICE

53880

DATE

8-31-22