



PATIENT

Chairman Meow
Wesierski

PRESENTING CLINICAL SIGNS

1 yo Maine Coon with chronic mild stertor, snoring and congestion lifelong. Ocular discharge as well. Mild nasal discharge. Ptosis OS noted on PE. No polyp seen. Open as to cause of stertor
Abnormal PE/Chem/CBC/UA Results: Ptosis OS, mild stertor. Mild gingivitis and stomatitis.
Normal CBC & Chem. FIV/FelLV negative

SPECIES

Feline

COMPUTED TOMOGRAPHIC STUDY OF THE HEAD

Plain and post contrast studies available for review in bone and soft tissue windows.

BREED

Maine Coon

COMPUTED TOMOGRAPHIC FINDINGS

The brain presents no deviation from normal anatomy and symmetry. The grey and white matter distinction and the neuroparenchymal attenuation are as expected. The distribution of contrast enhancement is within normal limits throughout the parenchyma and meninges. The ventricular system is non-dilated and within the limits of the expected volume and symmetry.

SEX

MN

Extensive mucosal swelling and turbinate destruction are noted within both nasal cavities. Distortion of the nasal bones is seen. The cribriform plate is intact. The left frontal sinus presents mild mucosal swelling. Mucosal swelling and hyperostosis of the lateral external and internal laminae of the left frontal sinus are seen. Nasopharyngeal mucosal swelling is noted. A defect is seen in the nasal septum in the rostral and mid third of the nasal cavities. At this time, there is no evidence of nasopharyngeal stenosis.

AGE

1 Year, 5 Months

Both temporomandibular joints present congruent joint spaces with even subchondral bone surfaces and are considered within normal limits.

INTERPRETED BY

Nele Eley, DVM
Dr. med. Vet. DipECVDI

Both tympanic bullae are aerated, the mucosal lining is not seen, the bony wall is smooth and thin. The external auditory meatuses present within normal limits.

HOSPITAL NAME

Animal Health
Partners

The bilateral submandibular, medial retropharyngeal, and parotid lymph nodes present mild symmetric enlargement.

The salivary glands present within normal limits.

The visible dentition is within normal limits.

REFERRING VET

Dr. Ashley Gold

COMPUTED TOMOGRAPHIC DIAGNOSIS

- Moderate to severe chronic bilateral destructive rhinosinusitis.
- Mild bilaterally symmetric submandibular, retropharyngeal, and parotid lymphadenomegaly.

INVOICE

59661

INTERPRETATION OF THE FINDINGS & FURTHER RECOMMENDATIONS

The CT study reveals moderate to severe bilateral chronic destructive rhinosinusitis which appears to correlate with the history of the nasal stertor. Chronic lymphoplasmacytic rhinitis is a primary differential diagnosis. However, infectious rhinitis such as viral, bacterial, mixed, or fungal cannot be ruled out as a potential differential diagnosis and rhinoscopy with sampling for culture (and histology) is recommended if not performed already.

DATE

8-3-23



PATIENT

The lymph node changes are compatible with reactive lymphadenitis.

Chairman Meow
Wesierski

SPECIES

Feline

BREED

Maine Coon

SEX

MN

AGE

1 Year, 5 Months

INTERPRETED BY

Nele Eley, DVM
Dr. med. Vet. DipECVDI

HOSPITAL NAME

Animal Health
Partners

REFERRING VET

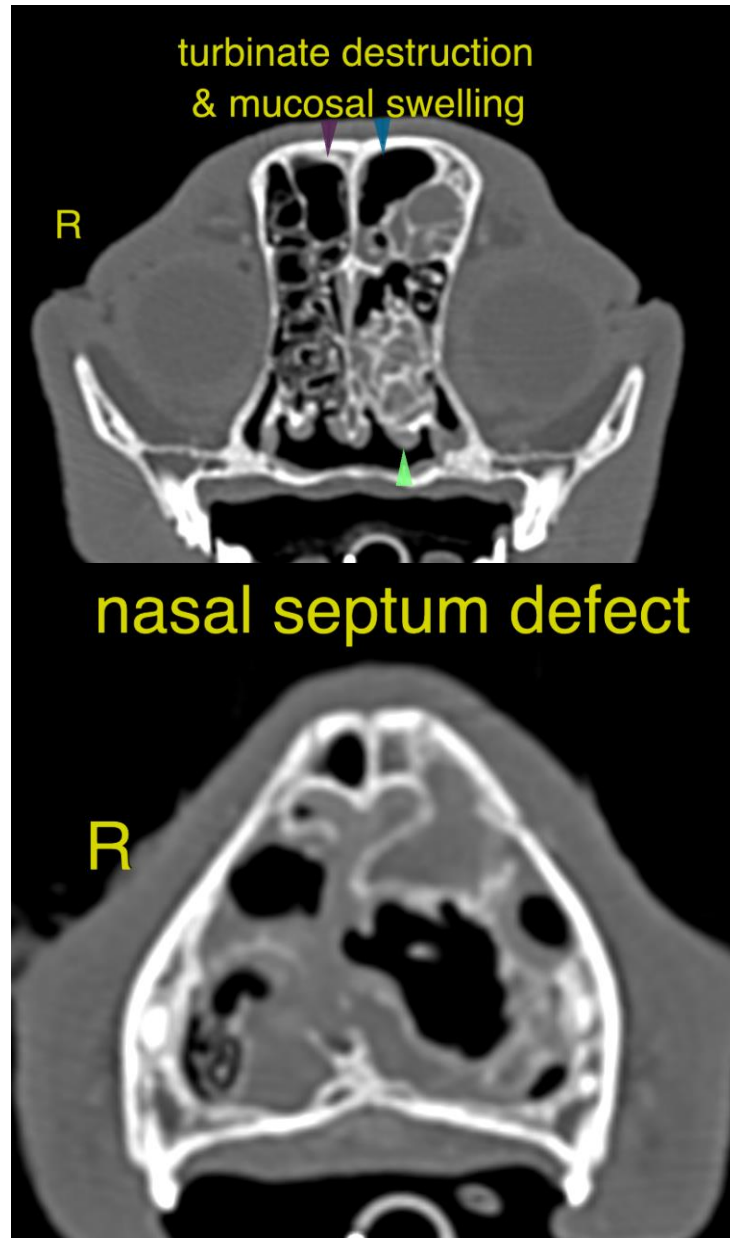
Dr. Ashley Gold

INVOICE

59661

DATE

8-3-23





PATIENT

Chairman Meow
Wesierski

The information and recommendations provided are based on the images presented by the referring veterinarian/sonographer. No evaluation can be communicated regarding pathology that was not visible in the image/video clips provided.

Thank you for this referral. If the clinical or image interpretation does not parallel your findings or if I can be of any further assistance please contact me.

SPECIES

Feline

Nele Eley, DVM, Dr. med. vet., DipECVDI
European Specialist in Veterinary Diagnostic Imaging, Cert. Radiology,
Senior lecturer University of Giessen, Germany, Veterinary Faculty, Department of Radiology
info@sonopath.com

BREED

Maine Coon

SEX

MN

AGE

1 Year, 5 Months

INTERPRETED BY

Nele Eley, DVM
Dr. med. Vet. DipECVDI

HOSPITAL NAME

Animal Health
Partners

REFERRING VET

Dr. Ashley Gold

INVOICE

59661

DATE

8-3-23