

**PATIENT**

Stanley Page

PRESENTING CLINICAL SIGNS

Presented for a mass on his throat, noticed by O on Monday. Likes to chew sticks. Attempted FNA, pure blood. Mouth examination unremarkable.

SPECIES

Canine

COMPUTED TOMOGRAPHIC STUDY OF THE NECK

Plain and post contrast studies available for review.

BREED

Cross Breed

COMPUTED TOMOGRAPHIC FINDINGS

A 4.0 cm long, 3.0 cm wide, and 2.0 cm high cavitory lesion is seen in the submandibular area to the right of the midline. The cavitory lesion is thick walled with peripheral rim enhancement, fluid attenuating cavitated center, and extensive peripheral fat stranding. No overt connection with the salivary glands is seen. There is a mild mass effect onto the basihyoid bone. Foreign material cannot be identified.

SEX

NM

The right submandibular lymph nodes are moderately enlarged. The right and left medial retropharyngeal lymph nodes present mild symmetric enlargement.

AGE

10 Years, 4 Months

Both lobes of the thyroid gland are seen and present within normal limits.

COMPUTED TOMOGRAPHIC DIAGNOSIS

- Cavitory lesion with peripheral cellulitis in the right submandibular area.
- Mild to moderate regional lymphadenomegaly compatible with reactive hyperplasia.

INTERPRETED BY

Nele Eley, DVM
Dr. med. Vet. DipECVDI

INTERPRETATION OF THE FINDINGS & FURTHER RECOMMENDATIONS

The CT findings are compatible with a right submandibular abscess. Foreign material cannot be identified. However, migrating foreign material or prior perforating injury is the most likely cause of the abscessation.

HOSPITAL NAME

Myerscough
Veterinary Group

The lymph node changes are compatible with reactive hyperplasia. No direct salivary gland involvement is seen.

REFERRING VET

Ioannis Kontos

Surgical abscess drainage is recommended. Note that small pieces of organic foreign material may be occult on CT. Hence, presence of such material cannot be ruled out entirely.

INVOICE

53249

DATE

8-3-22



PATIENT

Stanley Page

SPECIES

Canine

BREED

Cross Breed

SEX

NM

AGE

10 Years, 4 Months

INTERPRETED BY

Nele Eley, DVM
Dr. med. Vet. DipECVDI

HOSPITAL NAME

Myerscough
Veterinary Group

REFERRING VET

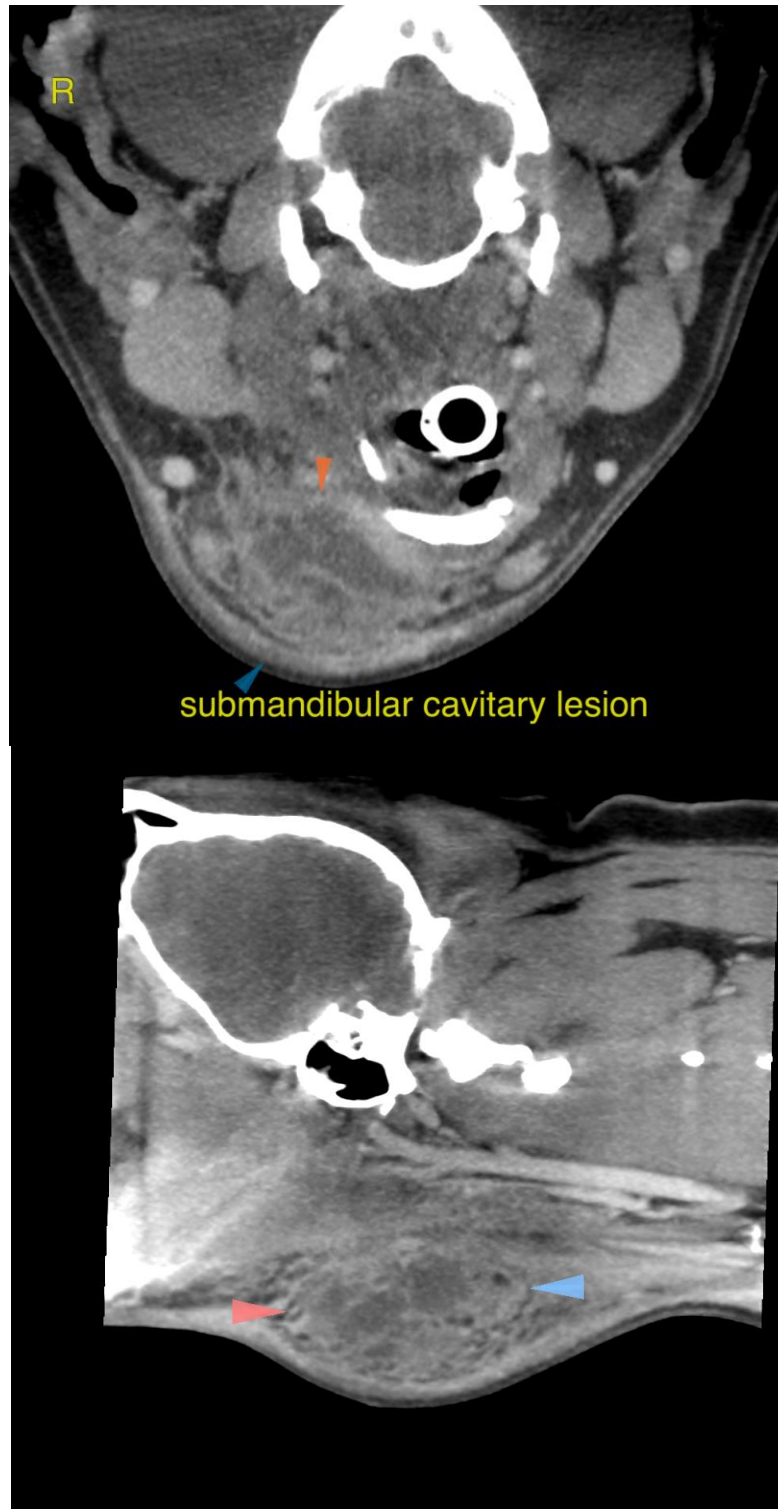
Ioannis Kontos

INVOICE

53249

DATE

8-3-22





PATIENT

Stanley Page

The information and recommendations provided are based on the images presented by the referring veterinarian/sonographer. No evaluation can be communicated regarding pathology that was not visible in the image/video clips provided.

SPECIES

Canine

Thank you for this referral. If the clinical or image interpretation does not parallel your findings or if I can be of any further assistance please contact me.

BREED

Cross Breed

Nele Eley, DVM, Dr. med. vet., DipECVDI
European Specialist in Veterinary Diagnostic Imaging, Cert. Radiology,
Senior lecturer University of Giessen, Germany, Veterinary Faculty, Department of Radiology
Nele.Eley@sonopath.com

SEX

NM

AGE

10 Years, 4 Months

INTERPRETED BY

Nele Eley, DVM
Dr. med. Vet. DipECVDI

HOSPITAL NAME

Myerscough
Veterinary Group

REFERRING VET

Ioannis Kontos

INVOICE

53249

DATE

8-3-22