



PATIENT

Millie McCoy

PRESENTING CLINICAL SIGNS

owner reports that she is panting more history of aspiration pneumonia 3/2022
Abnormal PE/Chem/CBC/UA Results: pending 3 radiographs pending chem/ cbc/ ua and 4dx

SPECIES

Canine

RADIOGRAPHIC STUDY OF THE THORAX

Right/left lateral and ventrodorsal views totaling 3 images available for review.

BREED

Labradoodle

RADIOGRAPHIC FINDINGS

The cardiac silhouette presents within normal limits. No cardiomegaly and no particular chamber enlargement is seen. The vertebral heart score is 9.4. There is no evidence of a vascular lung pattern.

SEX

FS

Course and width of the trachea are considered within normal limits.

There is no evidence of mediastinal widening.

AGE

1 Year

The lungs are deeply inflated. A moderate generalized bronchial lung pattern with mild peribronchial cuffing is seen. There are occasional pulmonary osteomas. No evidence of an alveolar infiltrate is noted.

RADIOGRAPHIC DIAGNOSIS

- Moderate generalized bronchial lung pattern.

INTERPRETED BY

Nele Eley, DVM
Dr. med. Vet. DipECVDI

INTERPRETATION OF THE FINDINGS & FURTHER RECOMMENDATIONS

The radiographic study reveals a moderate generalized bronchial lung pattern. Differential diagnosis includes prior bronchopneumonia/bronchitis as well as chronic active lower airway disease such as infectious bronchitis including viral, bacterial, and parasitic or eosinophilic bronchopneumopathy. Further definition by means of airway endoscopy with airway sampling could be considered.

At this point, there is no evidence of an alveolar infiltrate in terms of a new pneumonia.

HOSPITAL NAME

Northshore
Veterinary Hospital

REFERRING VET

Brita Kiffney

No esophageal dilation is seen.

INVOICE

53257

DATE

8-3-22



PATIENT

Millie McCoy

SPECIES

Canine

BREED

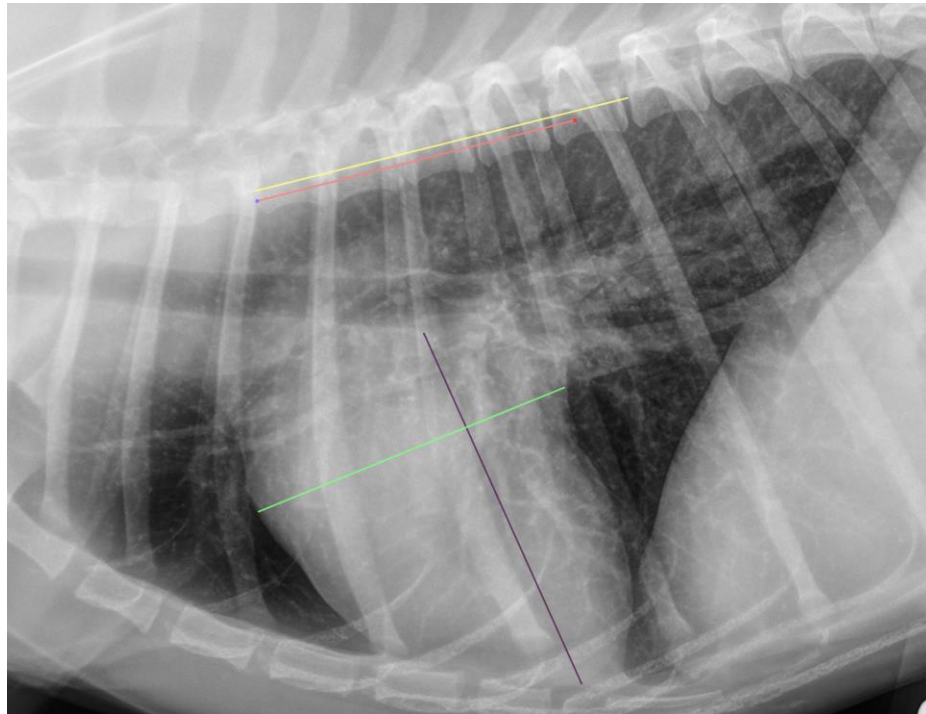
Labradoodle

SEX

FS

AGE

1 Year



INTERPRETED BY

Nele Eley, DVM
Dr. med. Vet. DipECVDI

The information and recommendations provided are based on the images presented by the referring veterinarian/sonographer. No evaluation can be communicated regarding pathology that was not visible in the image/video clips provided.

Thank you for this referral. If the clinical or image interpretation does not parallel your findings or if I can be of any further assistance please contact me.

HOSPITAL NAME

Northshore
Veterinary Hospital

Nele Eley, DVM, Dr. med. vet., DipECVDI
European Specialist in Veterinary Diagnostic Imaging, Cert. Radiology,
Senior lecturer University of Giessen, Germany, Veterinary Faculty, Department of Radiology
Nele.Eley@sonopath.com

REFERRING VET

Brita Kiffney

INVOICE

53257

DATE

8-3-22