

**PATIENT**

Macie Wallace

PRESENTING CLINICAL SIGNS

2 month history of left pelvic limb lameness, responsive to NSAID. No obvious gait abnormalities or other abnormal finding on physical exam. Left leg is forward and marked on images. 1 image is not marked as pet kicked off marker, the tail is pointed towards the right rear leg.

SPECIES

Canine

RADIOGRAPHIC STUDY OF THE STIFLES

Lateral and craniocaudal views of the stifles, lateral view of the tarsi, and ventrodorsal view of the pelvis totaling 5 images available for review.

BREED

Labrador Retriever

Stifle read requested.

SEX

Spayed Female

RADIOGRAPHIC FINDINGS

The left stifle presents moderate articular swelling. Moderate cranial thrust of the tibia and distal displacement of the popliteal sesamoid bone are seen. There is a moderate amount of periarticular osteophytes accentuating the fabellae, femoral trochlea, distal pole of the patella, and cranial margin of the tibial plateau.

AGE

4

Moderate atrophy of the left hind limb musculature is seen.

The projection of the right stifle is oblique and within normal limits as far as assessable.

INTERPRETED BY

Nele Eley, DVM
Dr. med. Vet. DipECVDI

RADIOGRAPHIC DIAGNOSIS

- Moderate left stifle osteoarthritis with radiographic evidence of cranial cruciate ligament failure.
- Disuse atrophy of the left hind limb musculature.

HOSPITAL NAME

Lambs Gap Animal
Hospital

INTERPRETATION OF THE FINDINGS & FURTHER RECOMMENDATIONS

The radiographic study confirms presence of failure of the function of the cranial cruciate ligament in the left stifle. Moderate osteoarthritic changes are seen. Concurrent meniscopopathy cannot be ruled out. Surgical intervention is indicated in order to address the presumed biomechanical instability and prevent further damage to the articular structures.

REFERRING VET

Dr. Cynthia Kinney

INVOICE

47154

DATE

8-26-21



PATIENT

Macie Wallace

SPECIES

Canine

BREED

Labrador Retriever

SEX

Spayed Female

AGE

4

INTERPRETED BY

Nele Eley, DVM
Dr. med. Vet. DipECVDI

HOSPITAL NAME

Lambs Gap Animal
Hospital

REFERRING VET

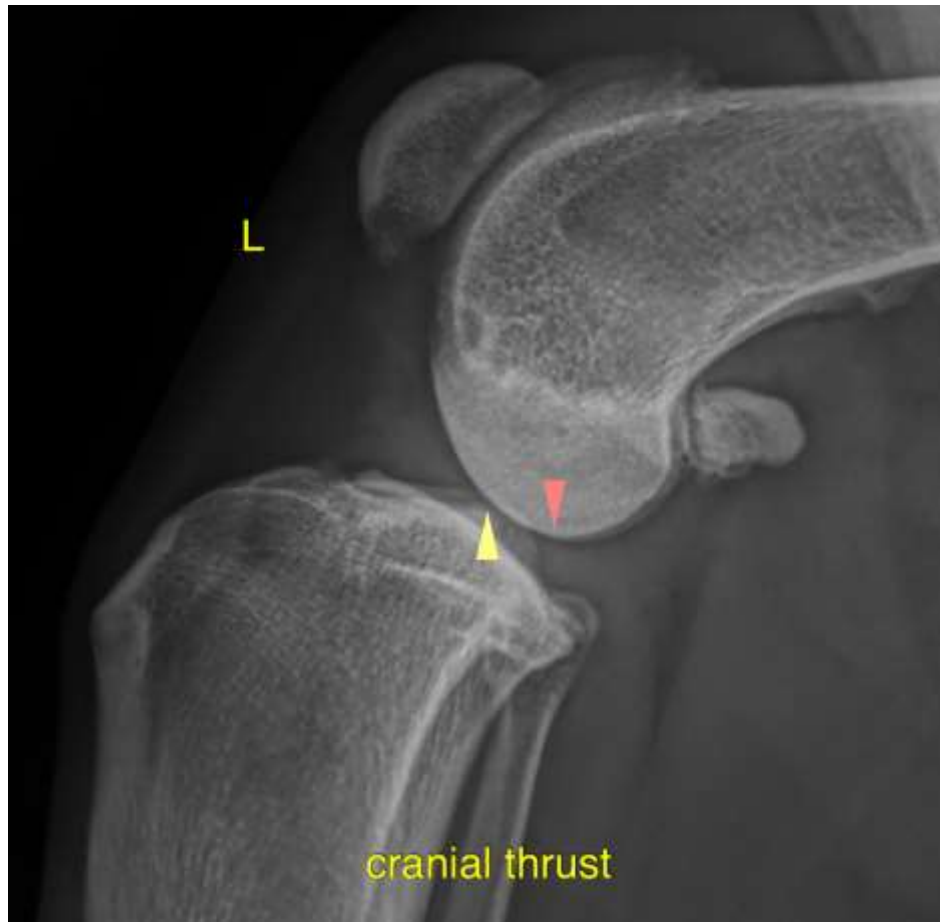
Dr. Cynthia Kinney

INVOICE

47154

DATE

8-26-21



The information and recommendations provided are based on the images presented by the referring veterinarian. No evaluation can be communicated regarding pathology that was not visible in the image/video clips provided.

Thank you for this referral. If the clinical or image interpretation does not parallel your findings or if I can be of any further assistance please contact me.

Nele Eley, DVM, Dr. med. vet., DipECVDI
European Specialist in Veterinary Diagnostic Imaging, Cert. Radiology,
Senior lecturer University of Giessen, Germany, Veterinary Faculty, Department of Radiology
Nele.Eley@sonopath.com