

**PATIENT**

Jimmy Roswell

PRESENTING CLINICAL SIGNS

Competition obedience dog with chronic lower back discomfort affecting sitting and lying posture. Targeted exercises demonstrate relative weakness of the left hindlimb. On examination, the only source of pain located was the left iliopsoas tendon. Lumbar, coxofemoral and stifle radiographs were normal

SPECIES

Canine

ULTRASONOGRAPHIC FINDINGS

The psoas major tendon presents within normal limits in both hind limbs. The tendon is thin, smoothly delineated, and the internal echoarchitecture is within normal limits with a well recognizable regularly structured fiber pattern.

BREED

Shetland Sheepdog

No evidence of avulsion or enthesophytosis is noted at the lesser trochanter of the femur. There is a mild concave indentation within the bone surface of the lesser trochanter on both sides which is considered a normal anatomic variant.

SEX

MN

The musculotendinous junction is smooth. No evidence of fiber disruption and peritendinous inflammation is seen.

AGE

4 Years

The muscle volume of the iliopsoas appears to be bilaterally symmetric. The echoarchitecture and echogenicity are within expected limits.

ULTRASONOGRAPHIC DIAGNOSIS

- Ultrasonographically normal iliopsoas muscles.

INTERPRETED BY

Nele Eley, DVM
Dr. med. Vet. DipECVDI

INTERPRETATION OF THE FINDINGS & FURTHER RECOMMENDATIONS

The ultrasonographic findings of the iliopsoas/psoas major were within normal limits in both hind limbs. With the pertinent clinical history, stage 1 microstructural damage of the left iliopsoas and/or psoas major appears to be a potential which is ultrasonographically occult and empirical management for iliopsoas musculotendinopathy including medical treatment and physical therapy could be considered despite the negative ultrasonographic findings.

HOSPITAL NAME

Points East West
Veterinary Services

REFERRING VET

David Lane

INVOICE

47160

DATE

8-26-21



PATIENT

Jimmy Roswell

SPECIES

Canine

BREED

Shetland Sheepdog

SEX

MN

AGE

4 Years

INTERPRETED BY

Nele Eley, DVM
Dr. med. Vet. DipECVDI

HOSPITAL NAME

Points East West
Veterinary Services

REFERRING VET

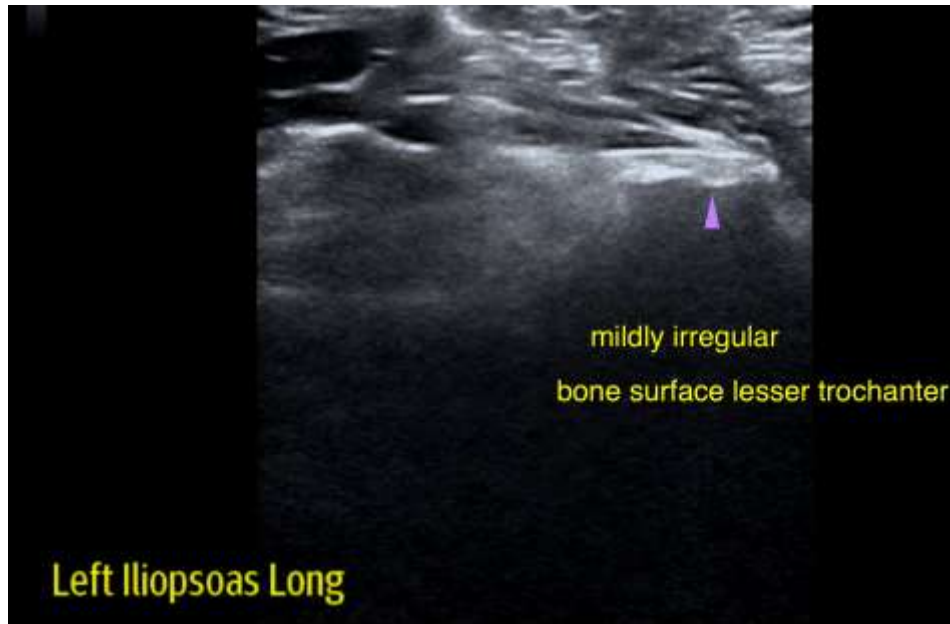
David Lane

INVOICE

47160

DATE

8-26-21



The information and recommendations provided are based on the images presented by the referring veterinarian. No evaluation can be communicated regarding pathology that was not visible in the image/video clips provided.

Thank you for this referral. If the clinical or image interpretation does not parallel your findings or if I can be of any further assistance please contact me.

Nele Eley, DVM, Dr. med. vet., DipECVDI
European Specialist in Veterinary Diagnostic Imaging, Cert. Radiology,
Senior lecturer University of Giessen, Germany, Veterinary Faculty, Department of Radiology
Nele.Eley@sonopath.com