

**PATIENT**

Ezekiel Martinez

PRESENTING CLINICAL SIGNS

Two nights ago, Ricky (owner) found Ezekiel laying down outside and not wanting to get up. He reports that when he does get up, he doesn't put weight on his right rear leg. He seems particularly painful when his upper thigh area is palpated. Ricky can't think of what may have happened - possibility of being kicked by mini horses. Ricky has given Ezekiel some CBD for the pain, and it seemed to help. He hasn't had issues like this in the past

Abnormal PE/Chem/CBC/UA Results: Ambulatory X 3, NON-WEIGHT BEARING ON RIGHT HIND LEG, CREPITUS AND PAIN WITH MANIPULATION OF UPPER LEG/HIP.

SPECIES

Canine

BREED

Great Pyrenees

RADIOGRAPHIC STUDY OF THE PELVIS

Ventrodorsal and lateral views of the pelvis totaling 3 images available for review.

RADIOGRAPHIC FINDINGS**SEX**

Neutered

There is cranial and dorsal luxation of the right femoral head.

An elongated wedge shaped fragment appears to be isolated from the caudolateral acetabular rim.

AGE

3 Years, 6 Months

No overtly dysplastic conformation of the right acetabulum and femoral head is seen.

There is a symmetric lumbosacral transitional vertebra.

INTERPRETED BY

Nele Eley, DVM
Dr. med. Vet. DipECVDI

RADIOGRAPHIC DIAGNOSIS

- Cranial and dorsal luxation of the right femoral head with presumed acetabular fracture.
- Congenital symmetric lumbosacral transitional vertebra.

HOSPITAL NAME

Elizabeth Animal
Hospital

INTERPRETATION OF THE FINDINGS & FURTHER RECOMMENDATIONS

The radiographic study reveals dorsal and cranial luxation of the right femoral head. There appears to be avulsion of the right caudolateral acetabular margin which is a contraindication for closed reduction and may prompt the need for surgery in order to either reduce the acetabular fracture and reposition the femoral head or to perform femoral head/neck ostectomy.

REFERRING VET

Kim Allyn, DVM

The presence of a congenital transitional lumbosacral vertebra is an incidental finding at this point. However, it may predispose to lumbosacral disc degeneration.

INVOICE

47157

DATE

8-26-21



PATIENT

Ezekiel Martinez

SPECIES

Canine

BREED

Great Pyrenees

SEX

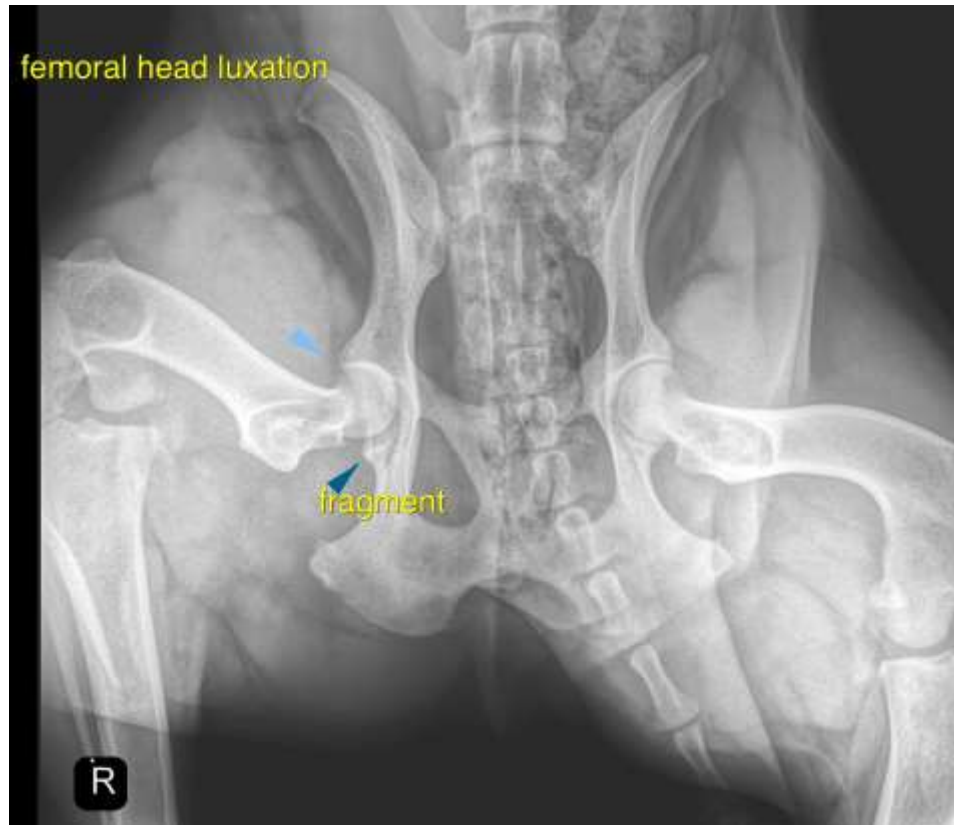
Neutered

AGE

3 Years, 6 Months

INTERPRETED BY

Nele Eley, DVM
Dr. med. Vet. DipECVDI



HOSPITAL NAME

Elizabeth Animal
Hospital

REFERRING VET

Kim Allyn, DVM

INVOICE

47157

DATE

8-26-21

The information and recommendations provided are based on the images presented by the referring veterinarian. No evaluation can be communicated regarding pathology that was not visible in the image/video clips provided.

Thank you for this referral. If the clinical or image interpretation does not parallel your findings or if I can be of any further assistance please contact me.

Nele Eley, DVM, Dr. med. vet., DipECVDI
European Specialist in Veterinary Diagnostic Imaging, Cert. Radiology,
Senior lecturer University of Giessen, Germany, Veterinary Faculty, Department of Radiology
Nele.Eley@sonopath.com