

**PATIENT**

Koby Petrunik

PRESENTING CLINICAL SIGNS

Coughing excessively. Grade 4 heart murmur

SPECIES

Canine

RADIOGRAPHIC STUDY OF THE THORAX

Right/left lateral and ventrodorsal whole body views totaling 6 images available for review.

Thoracic read requested.

BREED

Pomeranian Mix

RADIOGRAPHIC FINDINGS

Moderate left sided cardiomegaly with left atrial tenting and bronchial splitting is noted. The vertebral heart score is 12.

SEX

Male

There is a caudodorsal perihilar alveolar lung pattern and pulmonary venous dilation noted.

Severe collapse of the cervical and moderate collapse of the intrathoracic trachea are seen.

Mild hepatomegaly is noted.

AGE

7 Years

There is moderate gastric aerophagia in a post prandial stomach.

INTERPRETED BYNele Eley, DVM
Dr. med. Vet. DipECVDI

- Left sided cardiomegaly cardiogenic pulmonary edema.
- Dynamic tracheal collapse.
- Mild hepatomegaly.
- Aerophagia.

HOSPITAL NAMETruscott Animal
Hospital**INTERPRETATION OF THE FINDINGS & FURTHER RECOMMENDATIONS**

The radiographic study reveals left sided cardiomegaly with cardiogenic pulmonary edema in terms of congestive heart failure. Mitral valve regurgitation due to endocardiosis is thought to be the most likely underlying cause of the pertinent radiographic changes. An accurate diagnosis and detailed staging require a cardiac echo. The use of diuretics is indicated.

REFERRING VET

Dr. Medhat Meawad

There also is dynamic collapse of both the cervical and thoracic trachea.

Differentials for the hepatomegaly include metabolic/endocrine hepatopathy. A diffuse neoplastic or inflammatory infiltrates are thought unlikely but cannot be ruled out entirely.

INVOICE

47140

DATE

8-25-21



PATIENT

Koby Petrunik

SPECIES

Canine

BREED

Pomeranian Mix

SEX

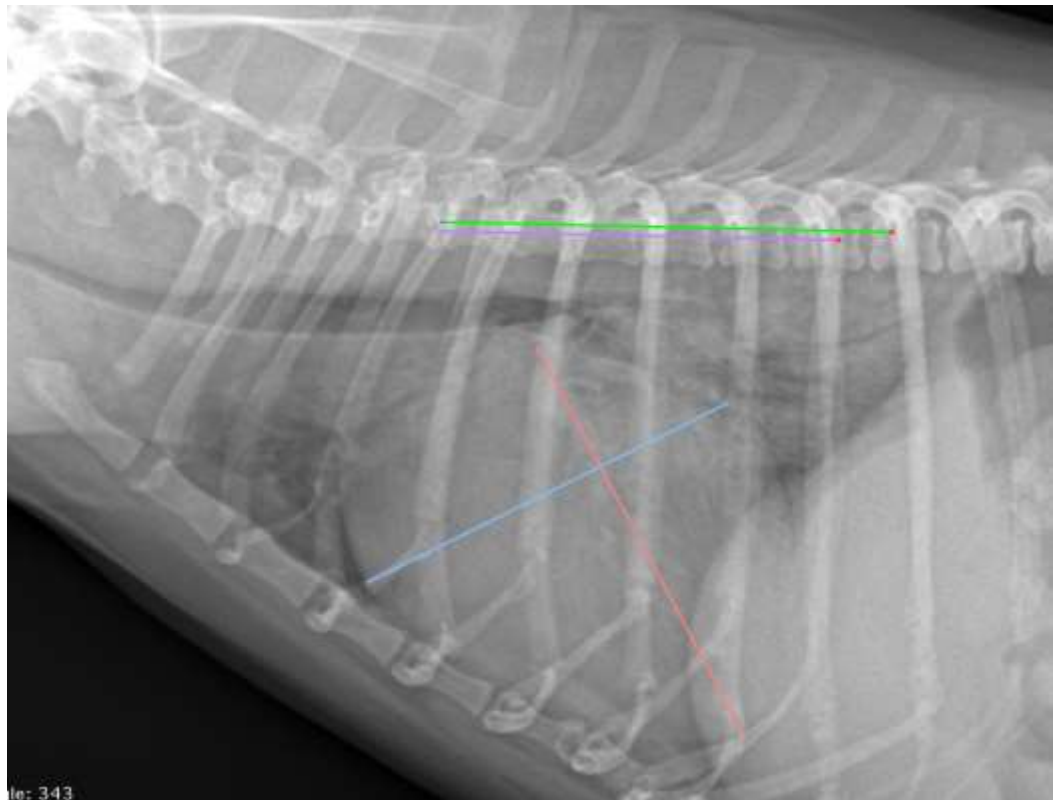
Male

AGE

7 Years

INTERPRETED BY

Nele Eley, DVM
Dr. med. Vet. DipECVDI



HOSPITAL NAME

Truscott Animal
Hospital

REFERRING VET

Dr. Medhat Meawad

The information and recommendations provided are based on the images presented by the referring veterinarian. No evaluation can be communicated regarding pathology that was not visible in the image/video clips provided.

Thank you for this referral. If the clinical or image interpretation does not parallel your findings or if I can be of any further assistance please contact me.

Nele Eley, DVM, Dr. med. vet., DipECVDI
European Specialist in Veterinary Diagnostic Imaging, Cert. Radiology,
Senior lecturer University of Giessen, Germany, Veterinary Faculty, Department of Radiology
Nele.Eley@sonopath.com

INVOICE

47140

DATE

8-25-21