

**PATIENT**

Joey Herman

PRESENTING CLINICAL SIGNS

1yo MN beagle with several week history of inappetence, lethargy, vomiting/diarrhea, and recent reluctance to jump on furniture. Joint taps suggestive of IMPA- starting on steroid therapy. Concern for possible changes on chest rads- pneumonia from previous vomiting? Want second opinion to decide if should add concurrent antibiotic therapy

SPECIES

Canine

RADIOGRAPHIC STUDY OF THE THORAX

Right/left lateral and ventrodorsal views totaling 3 images available for review.

BREED

Beagle

RADIOGRAPHIC FINDINGS

The surrounding bony structures are within normal limits.

SEX

Male

The extrathoracic soft tissues present homogeneous without abnormalities.

The heart is of normal size and shape and there is no evidence of cardiac chamber or vascular enlargement. The vertebral heart score is 10.2. The pulmonary vasculature is within normal limits.

AGE

1 Year

The cranial mediastinum presents the expected soft tissue opacity. The mediastinal width is less than twice the width of the vertebral column at the same level.

INTERPRETED BY

Nele Eley, DVM
Dr. med. Vet. DipECVDI

The trachea is normal in diameter and presents the anticipated course. The luminal outline of the trachea is smooth.

A minimal generalized bronchointerstitial lung pattern is seen. There is no evidence of alveolar infiltrates.

HOSPITAL NAME

Animal Health
Partners

The diaphragm is well delineated with even surface and the expected mild cranial bulging of the diaphragmatic cupola.

RADIOGRAPHIC DIAGNOSIS

- Normal thorax.

REFERRING VET

Dr. Shannon
Westgarth

INTERPRETATION OF THE FINDINGS & FURTHER RECOMMENDATIONS

No evidence of aspiration or other pneumonia is seen radiographically. The mild generalized enhancement of the interstitium and bronchial walls is thought to be within normal limits. Acute lower airway disease cannot be ruled out entirely as radiographic signs may lag behind the clinical changes. However, since this patient has no reported history of respiratory signs and negative radiographs, I do consider both airway and pulmonary pathology unlikely.

INVOICE

47130

DATE

8-25-21



PATIENT

Joey Herman

SPECIES

Canine

BREED

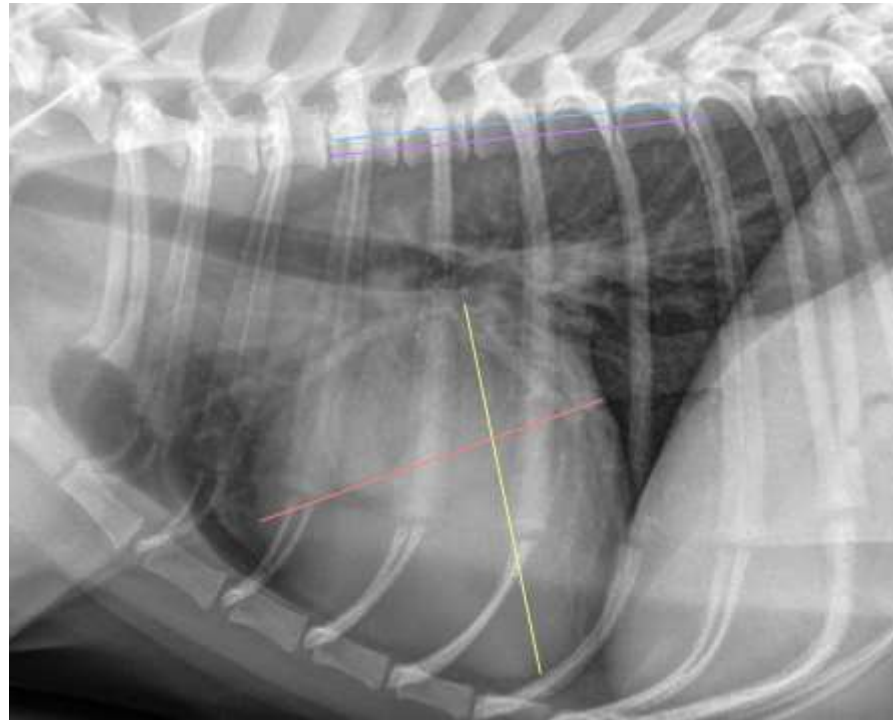
Beagle

SEX

Male

AGE

1 Year



INTERPRETED BY

Nele Eley, DVM
Dr. med. Vet. DipECVDI

The information and recommendations provided are based on the images presented by the referring veterinarian. No evaluation can be communicated regarding pathology that was not visible in the image/video clips provided.

HOSPITAL NAME

Animal Health
Partners

Thank you for this referral. If the clinical or image interpretation does not parallel your findings or if I can be of any further assistance please contact me.

Nele Eley, DVM, Dr. med. vet., DipECVDI
European Specialist in Veterinary Diagnostic Imaging, Cert. Radiology,
Senior lecturer University of Giessen, Germany, Veterinary Faculty, Department of Radiology
Nele.Eley@sonopath.com

REFERRING VET

Dr. Shannon
Westgarth

INVOICE

47130

DATE

8-25-21