

**PATIENT**

Ella Ditto

SPECIES

Canine

BREED

German Shepherd

SEX

Spayed Female

AGE

10 Years

INTERPRETED BYNele Eley, DVM
Dr. med. Vet. DipECVDI**HOSPITAL NAME**St. Catherine's Animal
Hospital**REFERRING VET**

Dr. Masoud

INVOICE

47132

DATE

8-25-21

PRESENTING CLINICAL SIGNS

Previously sent study for right hind leg to sonopath and came back no concerns, now Ella is being hospitalized with pancreatitis and not bearing any weight on back right leg with swelling to the hock joint .

Abnormal PE/Chem/CBC/UA Results: pancreatitis

RADIOGRAPHIC STUDY OF THE TARSI

Mediolateral view of the right tarsus and dorsoplantar view of both tarsal joints totaling 2 images available for review.

RADIOGRAPHIC FINDINGS

There is moderate soft tissue swelling circumferential to the right and left tarsus as well as the right metatarsus and hind paw. Mild soft tissue swelling appears to be present in the left metatarsal region as well.

There is a moderate amount of palisading periosteal new bone formation in the phalanges, metatarsal, and tarsal bones in both hind limbs accentuating the 2nd and 5th metatarsal bones as well as the lateral surface of the calcaneus in the left and right hind limb.

RADIOGRAPHIC DIAGNOSIS

- Polyostotic osteoproliferative periosteal osteopathy of both distal hind limbs with associated soft tissue swelling.

INTERPRETATION OF THE FINDINGS & FURTHER RECOMMENDATIONS

The radiographic findings are consistent with hypertrophic osteopathy, so called, Marie's disease which is associated with painful periosteal new bone formation in the distal limbs and typically a consequence of either intrathoracic or, which in this patient is more likely, intra-abdominal disease. The osseous and soft tissue changes typically resolve with treatment of the primary underlying pathology, provided successful treatment is possible.



PATIENT

Ella Ditto

SPECIES

Canine

BREED

German Shepherd

SEX

Spayed Female

AGE

10 Years

INTERPRETED BY

Nele Eley, DVM
Dr. med. Vet. DipECVDI

HOSPITAL NAME

St. Catherine's Animal
Hospital

REFERRING VET

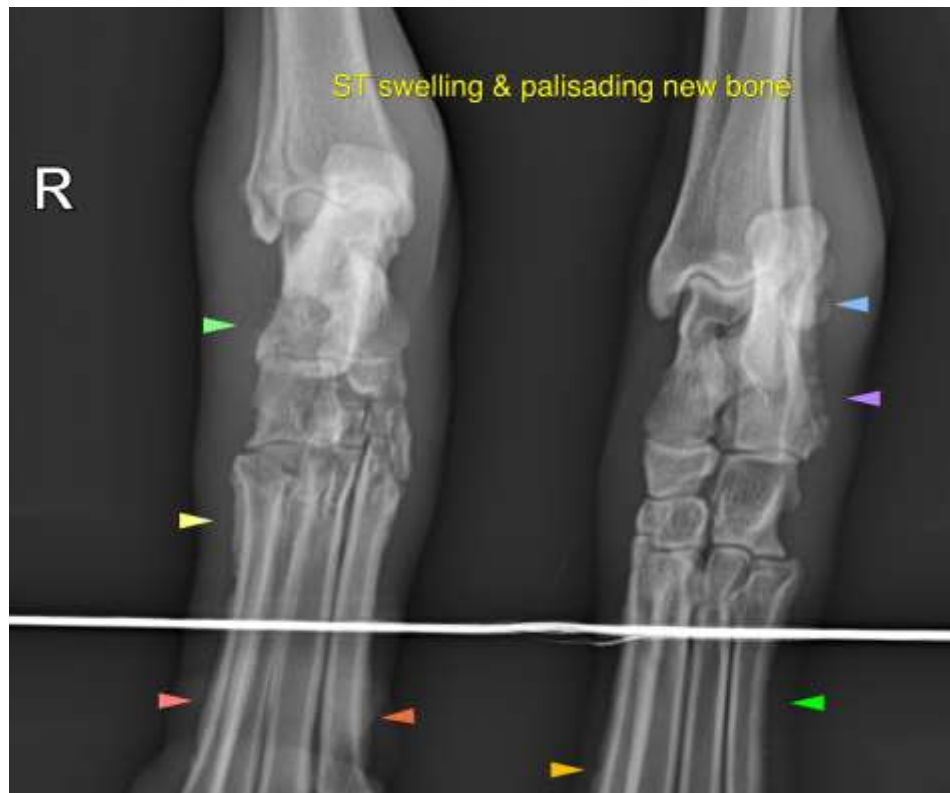
Dr. Masoud

INVOICE

47132

DATE

8-25-21



The information and recommendations provided are based on the images presented by the referring veterinarian. No evaluation can be communicated regarding pathology that was not visible in the image/video clips provided.

Thank you for this referral. If the clinical or image interpretation does not parallel your findings or if I can be of any further assistance please contact me.

Nele Eley, DVM, Dr. med. vet., DipECVDI
European Specialist in Veterinary Diagnostic Imaging, Cert. Radiology,
Senior lecturer University of Giessen, Germany, Veterinary Faculty, Department of Radiology
Nele.Eley@sonopath.com