

**PATIENT**

Tyber Brouillette

**PRESENTING CLINICAL SIGNS**

-1 week history of lump on neck, FNA to Vetlab suggested thyroid carcinoma/medullary carcinoma. -CBC/CHEM/T4/SDMA/4Dx – no significant findings -Lung rads no significant findings -Dog is bright alert and no changes to appetite etc.

**SPECIES**

Canine

**COMPUTED TOMOGRAPHIC STUDY OF THE NECK**

Plain and post contrast studies available for review.

**BREED**

German Shepherd

**COMPUTED TOMOGRAPHIC FINDINGS**

A 6.5 x 4.0 cm sized mass is emerging from the left lobe of the thyroid gland. Lesion margins are well delineated. Strong nonuniform contrast enhancement with multiple internal cavitations is seen. There is a mass effect onto the trachea, esophagus, common carotid artery, and surrounding hypaxial musculature with no evidence of peripheral tissue infiltration.

**SEX**

MN

The right lobe of the thyroid gland presents within normal limits.

The medial retropharyngeal lymph nodes present within normal limits.

**AGE**

5 Years

**COMPUTED TOMOGRAPHIC DIAGNOSIS**

- Mass of thyroidal origin in the left ventral neck.

**INTERPRETED BY**

Nele Eley, DVM  
Dr. med. Vet. DipECVDI

**INTERPRETATION OF THE FINDINGS & FURTHER RECOMMENDATIONS**

The CT findings are compatible with a neoplasia of the left thyroid gland. Adenoma and adenocarcinoma are primary differential diagnoses. At this time there is no evidence of metastatic disease to the retropharyngeal lymph nodes. Surgical excision of the mass could be discussed for this patient.

**HOSPITAL NAME**

Bridgwater  
Veterinary Hospital  
and Wellness Centre

**REFERRING VET**

Dr H. Bjornson

**INVOICE**

53713

**DATE**

8-24-22



**PATIENT**

Tyber Brouillette

**SPECIES**

Canine

**BREED**

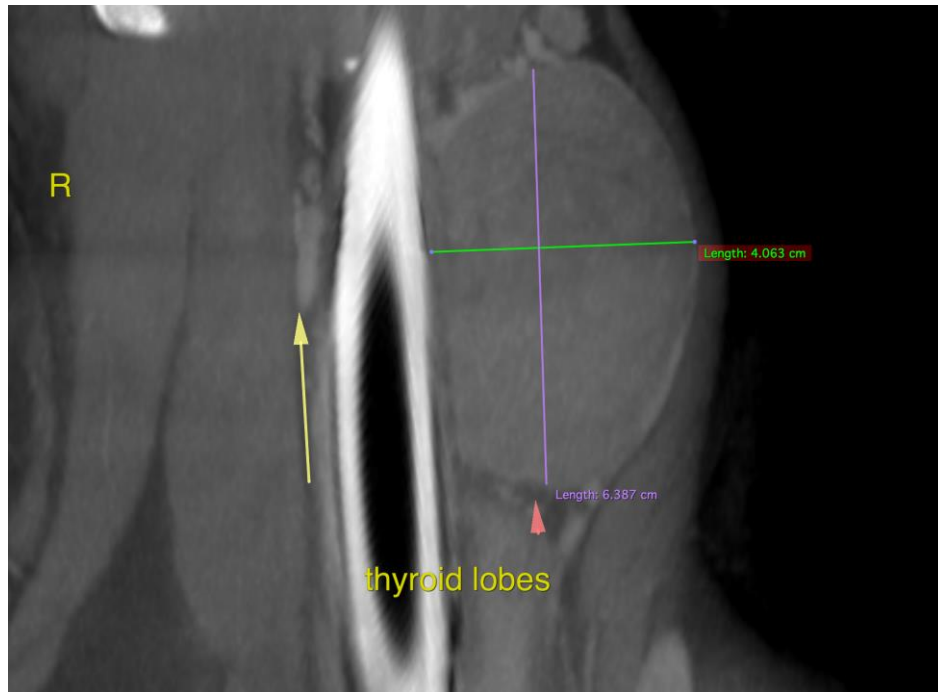
German Shepherd

**SEX**

MN

**AGE**

5 Years



**INTERPRETED BY**

Nele Eley, DVM  
Dr. med. Vet. DipECVDI

The information and recommendations provided are based on the images presented by the referring veterinarian/sonographer. No evaluation can be communicated regarding pathology that was not visible in the image/video clips provided.

**HOSPITAL NAME**

Bridgwater  
Veterinary Hospital  
and Wellness Centre

Thank you for this referral. If the clinical or image interpretation does not parallel your findings or if I can be of any further assistance please contact me.

**Nele Eley**, DVM, Dr. med. vet., DipECVDI  
European Specialist in Veterinary Diagnostic Imaging, Cert. Radiology,  
Senior lecturer University of Giessen, Germany, Veterinary Faculty, Department of Radiology  
Nele.Eley@sonopath.com

**REFERRING VET**

Dr H. Bjornson

**INVOICE**

53713

**DATE**

8-24-22