



PATIENT

Scout Hazlett

PRESENTING CLINICAL SIGNS

Hx reoccurring UTI's and urinary incontinence

SPECIES

Canine

COMPUTED TOMOGRAPHIC STUDY OF THE ABDOMEN

Plain and post contrast studies available for review.

BREED

Mastiff X

COMPUTED TOMOGRAPHIC FINDINGS

Both kidneys are irregular in shape with multiple surface retractions, irregular heterogeneous and weak nephrogram, disarranged appearance of renal cortex and medulla, as well as mild pyelectasia of 5mm on both sides. The right kidney measures 7.5 cm in length and the left kidney measures 5.0 cm in length.

SEX

FS

The urinary bladder is severely distended. No significant ureteral dilation is seen. The position of the ureteral papillae is considered within normal limits and approximately 1.3 cm cranial to the vesicourethral junction. No evidence of urethral leakage of contrast media is seen. Two normal jets level with the ureteral papillae can be identified.

AGE

8 Months

COMPUTED TOMOGRAPHIC DIAGNOSIS

- Bilateral nephropathy with suspicion of decreased renal excretion and disarranged organ architecture.
- No evidence of ureteral ectopia.

INTERPRETED BY

Nele Eley, DVM
Dr. med. Vet. DipECVDI

INTERPRETATION OF THE FINDINGS & FURTHER RECOMMENDATIONS

The CT study does not reveal ectopia of the ureters or other lower urinary tract abnormality, yet significant structural abnormality of both kidneys is seen. There are also signs of decreased renal function. Differential diagnosis includes congenital renal dysplasia as well as nephritis including pyelonephritis. The presence of concurrent lower urinary tract infection should be considered a potential.

HOSPITAL NAME

Animal Health
Partners

REFERRING VET

Dr. Westgarth

INVOICE

53699

DATE

8-24-22



PATIENT

Scout Hazlett

SPECIES

Canine

BREED

Mastiff X

SEX

FS

AGE

8 Months

INTERPRETED BY

Nele Eley, DVM
Dr. med. Vet. DipECVDI

HOSPITAL NAME

Animal Health
Partners

REFERRING VET

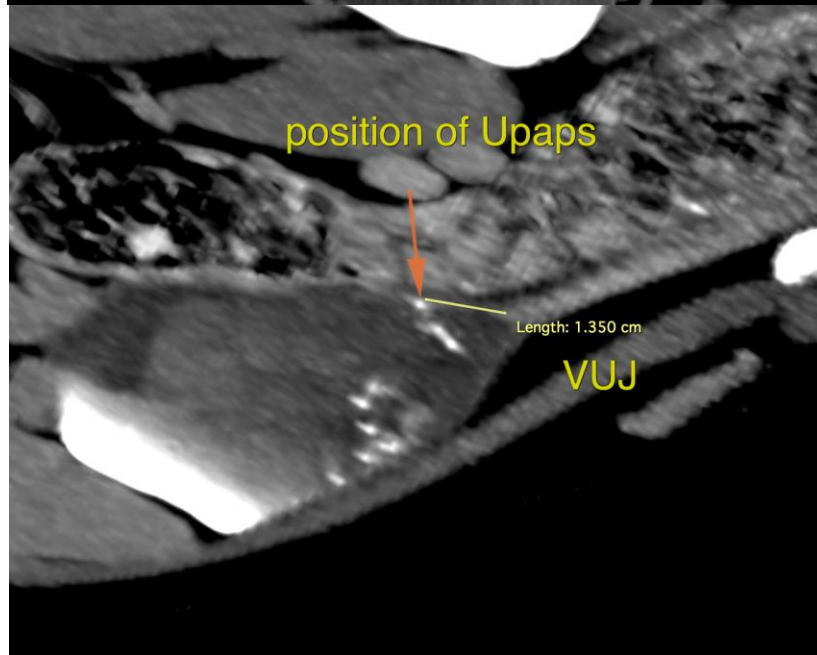
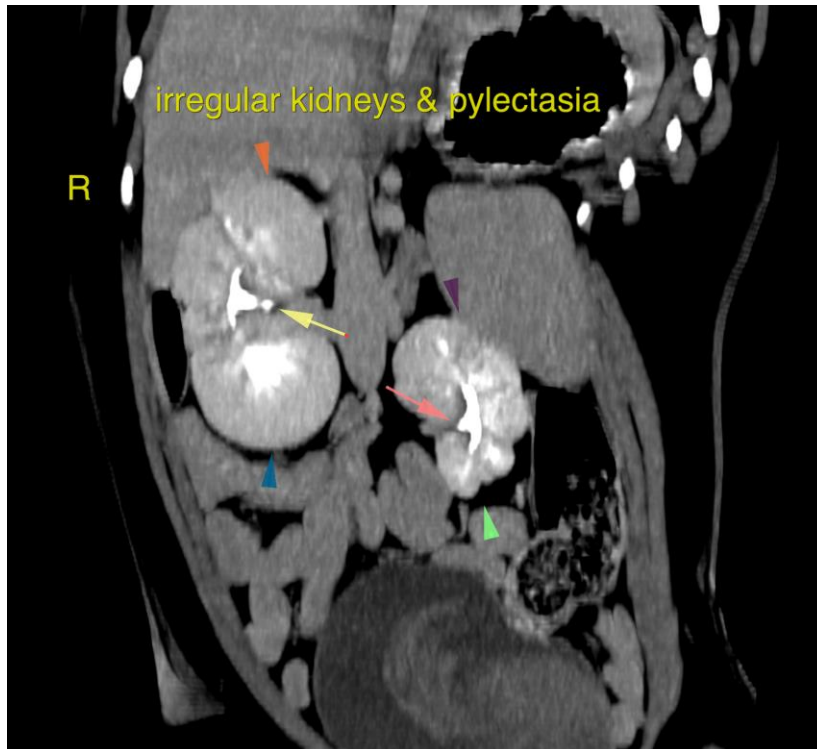
Dr. Westgarth

INVOICE

53699

DATE

8-24-22





PATIENT

Scout Hazlett

SPECIES

Canine

BREED

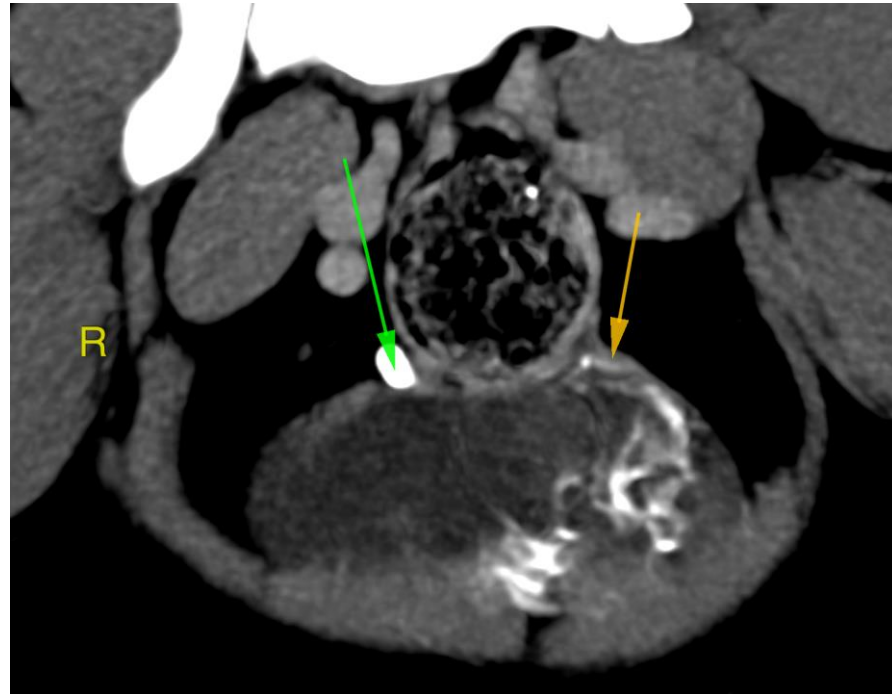
Mastiff X

SEX

FS

AGE

8 Months



INTERPRETED BY

Nele Eley, DVM
Dr. med. Vet. DipECVDI

The information and recommendations provided are based on the images presented by the referring veterinarian/sonographer. No evaluation can be communicated regarding pathology that was not visible in the image/video clips provided.

Thank you for this referral. If the clinical or image interpretation does not parallel your findings or if I can be of any further assistance please contact me.

HOSPITAL NAME

Animal Health
Partners

Nele Eley, DVM, Dr. med. vet., DipECVDI
European Specialist in Veterinary Diagnostic Imaging, Cert. Radiology,
Senior lecturer University of Giessen, Germany, Veterinary Faculty, Department of Radiology
Nele.Eley@sonopath.com

REFERRING VET

Dr. Westgarth

INVOICE

53699

DATE

8-24-22