



PATIENT

Hunter Noll

PRESENTING CLINICAL SIGNS

Chronic right shoulder

SPECIES

K9

ULTRASONOGRAPHIC FINDINGS

Right Shoulder

The supraspinatus tendon presents moderate to severe echoarchitectural remodeling with multiple shadowing echogenic foci. Volume increase of up to 9mm thickness of the supraspinatus tendon is seen causing significant biceps impingement.

BREED

Lab

The bicipital tendon sheath reveals moderate to severe thickening of its synovium. Severe almost tunnel shaped exostoses are seen within the intertubercular groove of the biceps tendon which limit the visibility of the bicipital tendon itself.

SEX

FS

ULTRASONOGRAPHIC DIAGNOSIS

- Moderate to severe chronic right supraspinatus tendinopathy with biceps impingement and moderate to severe biceps tenosynovitis.

AGE

8

INTERPRETATION OF THE FINDINGS & FURTHER RECOMMENDATIONS

The ultrasonographic findings are compatible with biceps impingement syndrome and moderate to severe chronic biceps tenosynovitis secondary to supraspinatus tendinopathy. These changes tend to be self-perpetual and slowly progressive. The visibility of the biceps tendon is limited owing to the presence of multiple osseous exostoses, some of them tunnel shaped within the intertubercular groove.

INTERPRETED BY

Nele Eley, DVM
Dr. med. Vet. DipECVDI

HOSPITAL NAME

Bayshore Veterinary
Hospital

REFERRING VET

Hunt

INVOICE

53687

DATE

8-24-22



PATIENT

Hunter Noll

SPECIES

K9

BREED

Lab

SEX

FS

AGE

8

INTERPRETED BY

Nele Eley, DVM
Dr. med. Vet. DipECVDI

HOSPITAL NAME

Bayshore Veterinary
Hospital

REFERRING VET

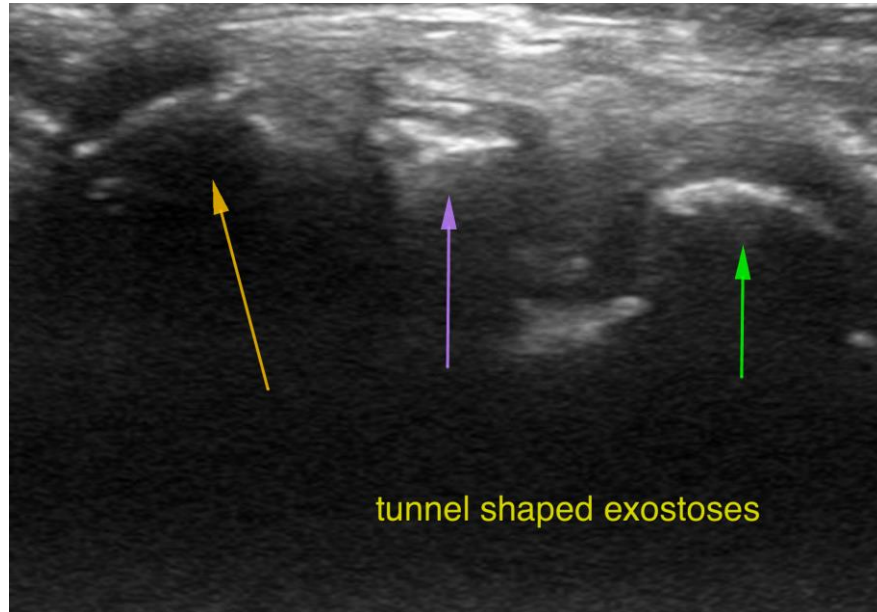
Hunt

INVOICE

53687

DATE

8-24-22



The information and recommendations provided are based on the images presented by the referring veterinarian/sonographer. No evaluation can be communicated regarding pathology that was not visible in the image/video clips provided.

Thank you for this referral. If the clinical or image interpretation does not parallel your findings or if I can be of any further assistance please contact me.

Nele Eley, DVM, Dr. med. vet., DipECVDI
European Specialist in Veterinary Diagnostic Imaging, Cert. Radiology,
Senior lecturer University of Giessen, Germany, Veterinary Faculty, Department of Radiology
Nele.Eley@sonopath.com