



PATIENT PRESENTING CLINICAL SIGNS

Cocoa Watchinski
Reason for Visit: Coughing History: Cocoa was brought in due to coughing Acute onset coughing last night, less cough this am. No cough since here.
Abnormal PE/Chem/CBC/UA Results: Hydration: N Mentation: N EENT: ears look great.
SPECIES Ventral iris pigmentation at 6 o'clock position OD...not raised Nucl Scl OU, iris atrophy OU Oral Cavity: mm pm heavy tartar, gingivitis Lymph Nodes: N Skin: N CV/Respiratory: No murmur, lungs clear, only able to elicit a very mild cough on tracheal palpation Abd/GI: N Uro/Perineum: N Musculoskeletal: N Neurological: N
Canine

BREED RADIOGRAPHIC STUDY OF THE THORAX

Poodle
Right lateral and ventrodorsal views totaling 2 images available for review.

RADIOGRAPHIC FINDINGS

SEX
NM
Course and width of the trachea are considered within normal limits. No evidence of bronchial collapse is seen.

There is a mild generalized bronchial lung pattern with mild multifocal peribronchial cuffing.

AGE
No evidence of mediastinal widening is noted.

9 Years, 8 Months
The cardiac silhouette presents no significant enlargement. The vertebral heart score is 10.5 which is within the reference range.

INTERPRETED BY
Moderate gastric aerophagia is noted.

Nele Eley, DVM
Dr. med. Vet. DipECVDI
There is mild generalized enlargement of the liver.

HOSPITAL NAME
A severe spondylosis deformans and narrowing of the intervertebral disc space are seen at T13/L1.

DPC Veterinary Hospital
RADIOGRAPHIC DIAGNOSIS

- Mild generalized bronchial lung pattern.
- Aerophagia.
- Hepatomegaly.
- Chronic intervertebral disc disease T13/L1.

REFERRING VET INTERPRETATION OF THE FINDINGS & FURTHER RECOMMENDATIONS

Dr. Feldt

INVOICE
No radiographic evidence of tracheal collapse is seen. However, dynamic tracheal disease cannot be ruled out.

53680

DATE
There is a mild bronchial lung pattern which may be within age related normal limits. Chronic lower airway disease such as eosinophilic bronchopneumopathy or infectious bronchitis such as viral, bacterial, and less likely parasitic cannot be ruled out entirely. Further definition by means of a clinical trial of treatment for bronchitis versus endoscopy with airway sampling could be considered.

8-24-22



PATIENT

Cocoa Watchinski

Differential diagnosis for the hepatomegaly includes vacuolar, metabolic, and endocrine hepatopathy and less likely diffuse inflammation, infection, or infiltrate disease. Correlate with the laboratory values to determine the necessity for further definition by means of ultrasound with eventual parenchymal sampling.

SPECIES

Canine

The aerophagia may be due to respiratory distress, general excitement, or pain.

BREED

Poodle

SEX

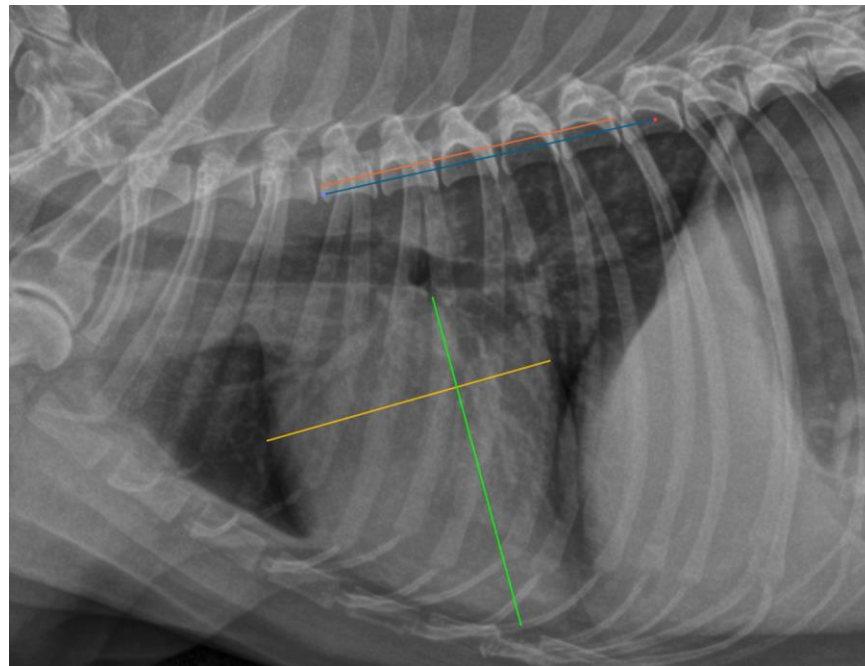
NM

AGE

9 Years, 8 Months

INTERPRETED BY

Nele Eley, DVM
Dr. med. Vet. DipECVDI



HOSPITAL NAME

DPC Veterinary
Hospital

REFERRING VET

Dr. Feldt

The information and recommendations provided are based on the images presented by the referring veterinarian/sonographer. No evaluation can be communicated regarding pathology that was not visible in the image/video clips provided.

Thank you for this referral. If the clinical or image interpretation does not parallel your findings or if I can be of any further assistance please contact me.

INVOICE

53680

Nele Eley, DVM, Dr. med. vet., DipECVDI
European Specialist in Veterinary Diagnostic Imaging, Cert. Radiology,
Senior lecturer University of Giessen, Germany, Veterinary Faculty, Department of Radiology
Nele.Eley@sonopath.com

DATE

8-24-22