



PATIENT

Chloe Bush

PRESENTING CLINICAL SIGNS

Met check

SPECIES

K9

RADIOGRAPHIC STUDY OF THE THORAX

Right/left lateral and ventrodorsal views totaling 4 images available for review.

RADIOGRAPHIC FINDINGS

BREED

Mastiff Mix

Ventrally bridging spondyloses are present between T11/12 and T12/13.

The heart is of normal size and shape and there is no evidence of specific chamber enlargement. No evidence of congestive heart failure is noted. The vertebral heart score is 9. The pulmonary vasculature is within normal limits.

SEX

SF

The cranial mediastinum presents the expected soft tissue opacity. The mediastinal width is less than twice the width of the vertebral column at the same level.

AGE

7

The trachea is normal in diameter and presents the anticipated course. The luminal outline of the trachea is smooth.

Mild esophageal aerophagia is noted and indicated by a tracheal stripe sign.

A mild generalized bronchial lung pattern is noted with even distribution throughout the lung. Occasional age related incidental pulmonary osteomas are seen. There is no evidence of pulmonary nodules or masses.

The diaphragm is well delineated with even surface and the expected mild cranial bulging of the diaphragmatic cupola.

There is moderate gastric aerophagia.

INTERPRETED BY

Nele Eley, DVM
Dr. med. Vet. DipECVDI

HOSPITAL NAME

All Creatures Animal
Hospital Stuart

RADIOGRAPHIC DIAGNOSIS

- No evidence of pulmonary metastatic disease.
- Normal age related presentation of the thorax.

REFERRING VET

Dr Mary Bressman

INTERPRETATION OF THE FINDINGS & FURTHER RECOMMENDATIONS

A mild bronchial lung pattern is noted and may be within age related normal limits. In case of coexisting clinical signs, the possibilities of allergic or infectious bronchopneumopathy should be considered. There was no evidence of pulmonary nodules or masses and no evidence of mediastinal lymphadenomegaly noted.

INVOICE

53683

The aerophagia is likely due to general excitement, pain, and less likely respiratory distress.

DATE

8-24-22



PATIENT

Chloe Bush

SPECIES

K9

BREED

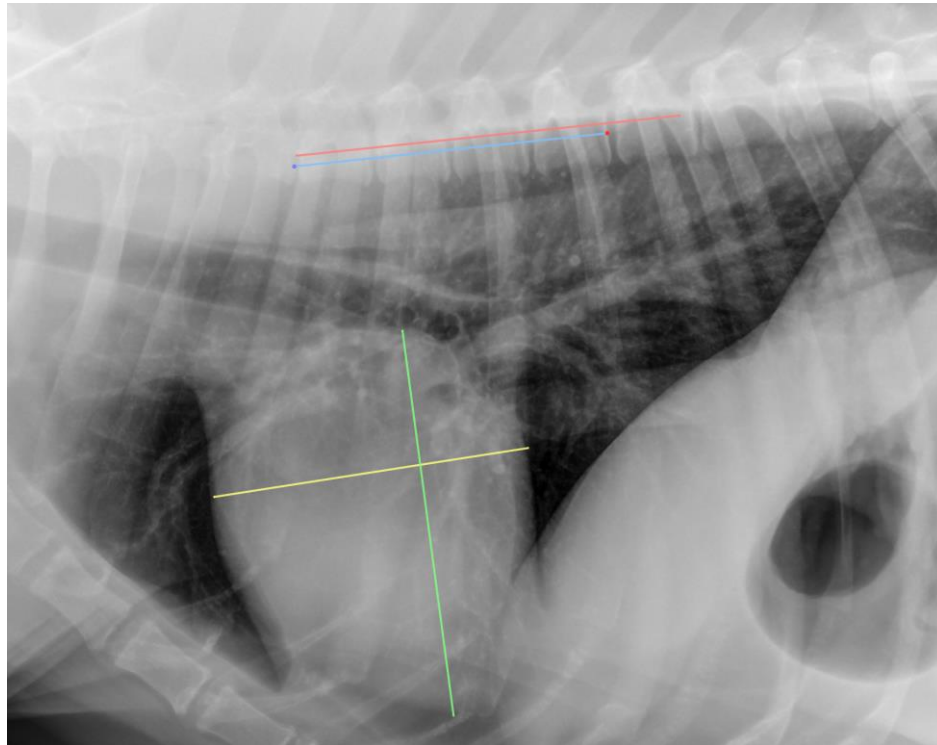
Mastiff Mix

SEX

SF

AGE

7



INTERPRETED BY

Nele Eley, DVM
Dr. med. Vet. DipECVDI

The information and recommendations provided are based on the images presented by the referring veterinarian/sonographer. No evaluation can be communicated regarding pathology that was not visible in the image/video clips provided.

HOSPITAL NAME

All Creatures Animal
Hospital Stuart

Thank you for this referral. If the clinical or image interpretation does not parallel your findings or if I can be of any further assistance please contact me.

Nele Eley, DVM, Dr. med. vet., DipECVDI
European Specialist in Veterinary Diagnostic Imaging, Cert. Radiology,
Senior lecturer University of Giessen, Germany, Veterinary Faculty, Department of Radiology
Nele.Eley@sonopath.com

REFERRING VET

Dr Mary Bressman

INVOICE

53683

DATE

8-24-22