



PATIENT

Maisy Shirer

PRESENTING CLINICAL SIGNS

Limping on and off - owner thought left rear but upon exam looked like the right rear was bothering her.
Abnormal PE/Chem/CBC/UA Results: Limping on right rear and pain on palpation

SPECIES

Canine

RADIOGRAPHIC STUDY OF THE PELVIS & STIFLES

Ventrodorsal view of the pelvis and mediolateral views of both stifles totaling 3 images available for review.

BREED

Terrier Mix

RADIOGRAPHIC FINDINGS

Pelvis

The coxofemoral joints present within normal limits. No evidence of osteoarthritis or dysplasia is seen.

SEX

FS

There is bilateral symmetry of the pelvic bones.

AGE

7 Years, 8 Months

Mild atrophy of the right hind limb's musculature appears to be present.

Stifles

The patella are in situ in both stifle joints.

INTERPRETED BY

Nele Eley, DVM
Dr. med. Vet. DipECVDI

Moderate articular swelling of the right stifle joint is seen as well as mild osteophytosis accentuating the femoral trochlear, distal pole of the patellar, and tibial plateau. There is no evidence of cranial thrust of the tibia and no significant displacement of the popliteal sesamoid bone.

HOSPITAL NAME

Elizabeth Animal
Hospital

The radiographic presentation of the left stifle is within normal limits.

RADIOGRAPHIC DIAGNOSIS

- Right stifle arthropathy with mild osteoarthritis and moderate articular swelling.
- Mild disuse atrophy of the right hind limb musculature.
- Radiographically normal coxofemoral joints and left stifle.

REFERRING VET

Kim Allyn, DVM

INTERPRETATION OF THE FINDINGS & FURTHER RECOMMENDATIONS

The radiographic findings suggest presence of mild to moderate osteoarthritis of the right stifle joint. Potential underlying causes include patella luxation, cranial cruciate ligament pathology, and meniscopathy. Non-orthopedic pathology including immune mediated arthritis can never be ruled out entirely. Clinical correlation is required.

INVOICE

47117

DATE

8-24-21



PATIENT

Maisy Shirer

SPECIES

Canine

BREED

Terrier Mix

SEX

FS

AGE

7 Years, 8 Months

INTERPRETED BY

Nele Eley, DVM
Dr. med. Vet. DipECVDI

HOSPITAL NAME

Elizabeth Animal
Hospital

REFERRING VET

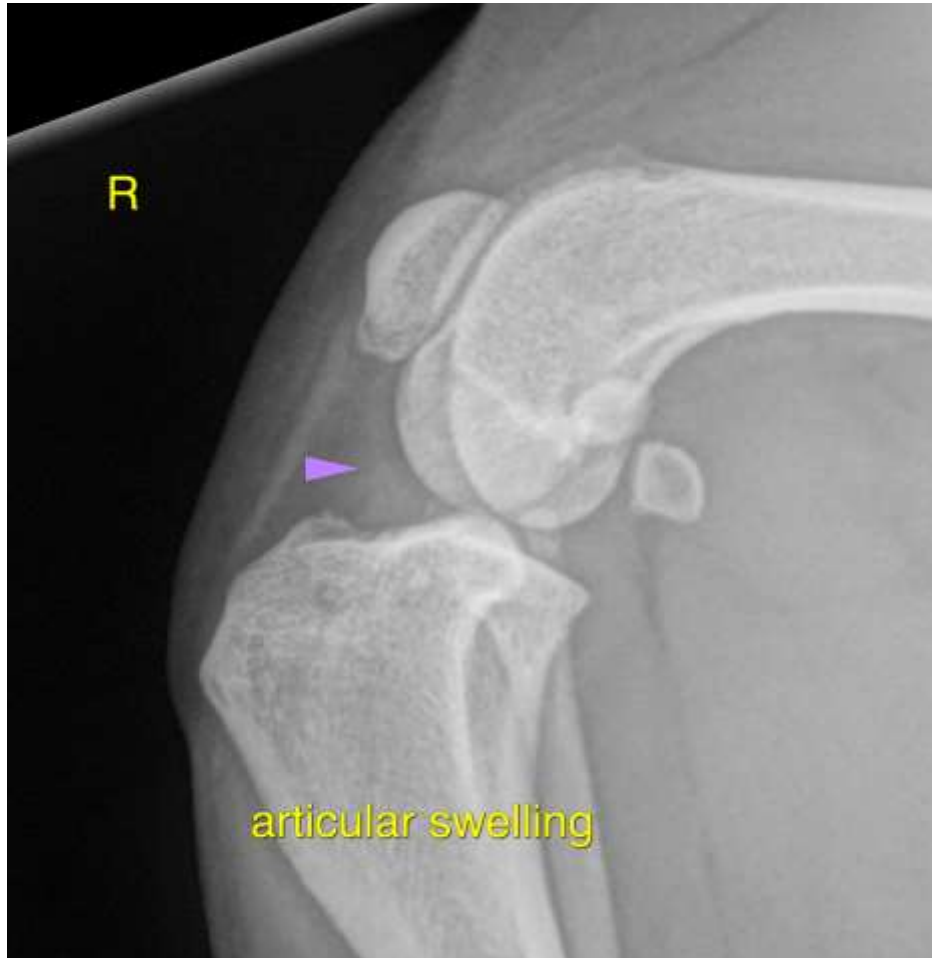
Kim Allyn, DVM

INVOICE

47117

DATE

8-24-21



The information and recommendations provided are based on the images presented by the referring veterinarian. No evaluation can be communicated regarding pathology that was not visible in the image/video clips provided.

Thank you for this referral. If the clinical or image interpretation does not parallel your findings or if I can be of any further assistance please contact me.

Nele Eley, DVM, Dr. med. vet., DipECVDI
European Specialist in Veterinary Diagnostic Imaging, Cert. Radiology,
Senior lecturer University of Giessen, Germany, Veterinary Faculty, Department of Radiology
Nele.Eley@sonopath.com