



PATIENT PRESENTING CLINICAL SIGNS

BONNIE PIDGEON

Date: 8/13/2021 Chief Complaint: adr/painful? History: excessive thirst/licking everything, especially when o palpates/rubs pets back, abdomen. service dog, o is concerned painful. Always a big drinker, chronic intermittent ALT elevation. Nomrmal bile acids. Liver biopsy WNL. Copper storage disease runs in family but no evidence on biopsy with Bonnie. Have never been able to find cause of her drinking more and intermittent ALT elevation. Very active, plays rough with other labs in house. normal labwork 4 months ago Per Mrs OFA x-rays...Hips excellent, elbows very good and normal echo from cardiologist Musculoskeletal: painful extension of left shoulder and movement of head to right. Mrs got discomfort on palpation of ileopsoas muscle, I did not get a response. No back pain. No CP deficits Date: 8/24/2021 Rechecking: left shoulder pain + cervical pain History: P presents for recheck of pain on left shoulder extension and cervical pain. O has been laser P at home herself and been giving gabapentin and gallirpant bu no improvemetns. P will yelp at times and lick her lips and pant at rest at home. Exam Notes: BAR, GOOD ROM IN NECK TODAY, NO PAIN ON PALPATION OF NECK. STILL PAINFUL ON EXT OF LEFT SHOULDER +/- ON PALPATION OF LEFT PECTORALS. NO PALPABLE MASSES IN AREA OF SHOULDER OR ARMPIT. NO PAIN IN ELBOWS. REAR LEGS PALPATE NORMALLY

SPECIES

Canine

BREED

Goldendoodle

SEX

FS

AGE

4.4 Years

INTERPRETED BY

Nele Eley, DVM
Dr. med. Vet. DipECVDI

HOSPITAL NAME

DPC Veterinary
Hospital

REFERRING VET

Dr. Feldt

INVOICE

47119

DATE

8-24-21

RADIOGRAPHIC STUDY OF THE SHOULDERS

Mediolateral and craniocaudal views of both shoulders totaling 3 images available for review.

RADIOGRAPHIC FINDINGS

The radiographic presentation of the shoulders is within normal limits. There is no evidence of osseous abnormalities. The subchondral bone surfaces of both shoulder joints present intact and smooth. There is no evidence of osteoarthritic changes. The intertubercular groove of the biceps tendon and greater humeral tubercle present within normal limits.

Mild spondylosis deformans and intervertebral disc space narrowing appears to be present at C4/5.

RADIOGRAPHIC DIAGNOSIS

- Radiographically normal shoulders.
- Spondylosis C4/5.

INTERPRETATION OF THE FINDINGS & FURTHER RECOMMENDATIONS

The osseous structures of the shoulders present within normal limits. Consider presence of soft tissue trauma or inflammation in the shoulder such as rotator cuff or biceps injury. If these are primary suspicions, based on the clinical examination, further definition could be considered by means of ultrasound or MRI. The MRI would allow to evaluate for potential cervical spinal disease at the same time.



PATIENT

BONNIE PIDGEON

SPECIES

Canine

BREED

Goldendoodle

SEX

FS

AGE

4.4 Years

INTERPRETED BY

Nele Eley, DVM
Dr. med. Vet. DipECVDI

HOSPITAL NAME

DPC Veterinary
Hospital

REFERRING VET

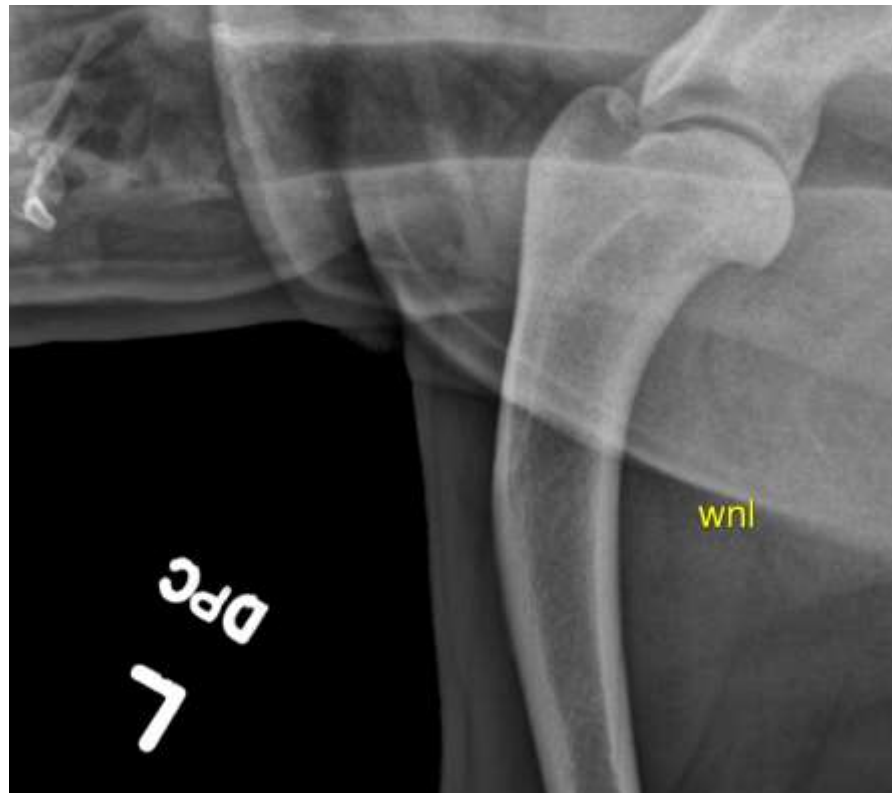
Dr. Feldt

INVOICE

47119

DATE

8-24-21



The information and recommendations provided are based on the images presented by the referring veterinarian. No evaluation can be communicated regarding pathology that was not visible in the image/video clips provided.

Thank you for this referral. If the clinical or image interpretation does not parallel your findings or if I can be of any further assistance please contact me.

Nele Eley, DVM, Dr. med. vet., DipECVDI
European Specialist in Veterinary Diagnostic Imaging, Cert. Radiology,
Senior lecturer University of Giessen, Germany, Veterinary Faculty, Department of Radiology
Nele.Eley@sonopath.com