



**PATIENT**

Domino Larocque

**PRESENTING CLINICAL SIGNS**

Chronic sneezing for greater than one year. Antibiotics only temporarily effective. History of snuffles.

**SPECIES**

Lagomorph

**COMPUTED TOMOGRAPHIC STUDY OF THE HEAD, NECK, & THORAX**

Plain and post contrast studies available for review.

**BREED**

Dwarf

**COMPUTED TOMOGRAPHIC FINDINGS**

**Head & Neck**

Moderate asymmetric and multifocal mucosal swelling is seen within both nasal cavities. There is a moderate amount of fluid accumulating between the nasal turbinates and within the frontal sinuses.

**SEX**

MN

The left tympanic bulla contains a moderate amount of fluid attenuating material and presents mild thickening of its osseous lining.

**AGE**

6 Years

The bilateral submandibular and retropharyngeal lymph nodes are mildly enlarged.

**Thorax**

The bony and surrounding soft tissue structures are within normal limits.

**INTERPRETED BY**

Nele Eley, DVM  
Dr. med. Vet. DipECVDI

The sternal, cranial mediastinal and tracheobronchial lymph nodes are small elongated with a normal short-to-long-axis-ratio is < 0.5, the attenuation and contrast enhancement pattern are uniform and considered within normal limits.

**HOSPITAL NAME**

Bridgwater  
Veterinary Hospital  
and Wellness Centre

The cardiovascular structures including the pulmonary vasculature are within normal limits.

The bronchial tree presents with regular branching and tapers uniformly towards the periphery as expected, the bronchial walls are thin and smooth. The bronchus-to-artery ratio is within normal limits.

Mild atelectatic changes of the left lung are seen.

**REFERRING VET**

Dr. Mooi

Small incidental gas pockets are seen within the esophageal lumen, there is no evidence of abnormal dilation.

**COMPUTED TOMOGRAPHIC DIAGNOSIS**

**INVOICE**

59890

- Moderate chronic bilateral destructive rhinosinusitis.
- Moderate chronic left hand sided otitis media.
- Mild bilaterally symmetric submandibular and medial retropharyngeal lymphadenomegaly.
- No structural bronchopulmonary changes.
- No evidence of mediastinal lymphadenomegaly.

**DATE**

8-23-23



**PATIENT**

Domino Larocque

**SPECIES**

Lagomorph

**BREED**

Dwarf

**SEX**

MN

**AGE**

6 Years

**INTERPRETED BY**

Nele Eley, DVM  
Dr. med. Vet. DipECVDI

**HOSPITAL NAME**

Bridgwater  
Veterinary Hospital  
and Wellness Centre

**REFERRING VET**

Dr. Mooi

**INVOICE**

59890

**DATE**

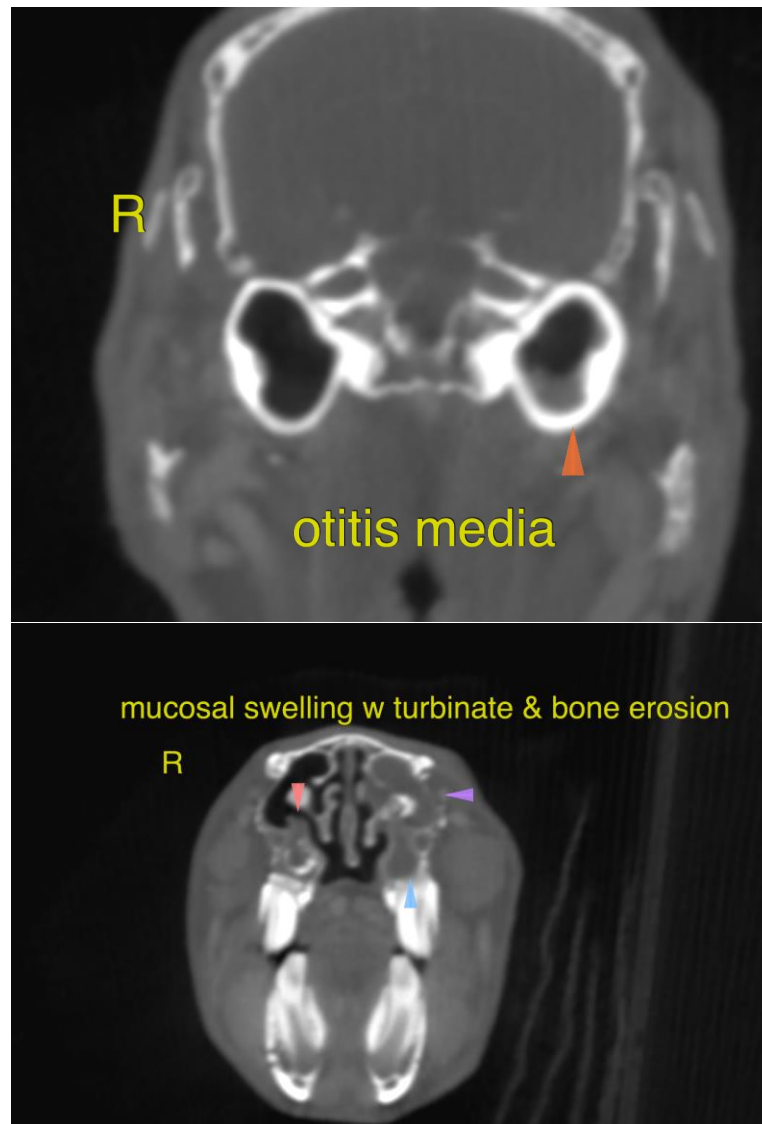
8-23-23

**INTERPRETATION OF THE FINDINGS & FURTHER RECOMMENDATIONS**

The CT findings are compatible with chronic destructive rhinosinusitis. Infectious rhinitis such as viral, bacterial, or mixed is considered likely. Lymphoplasmacytic or allergic rhinitis cannot be ruled out entirely but is thought by far less likely. No underlying dental issues or foreign material was identified.

The lymph node changes are compatible with reactive lymphadenitis.

The CT study does not reveal evidence of structural bronchopulmonary changes at this point; however, the CT findings may lag behind the clinical signs and concurrent lower airway involvement can never be ruled out entirely in spite of negative CT or radiographic findings.





**PATIENT**

Domino Larocque

The information and recommendations provided are based on the images presented by the referring veterinarian/sonographer. No evaluation can be communicated regarding pathology that was not visible in the image/video clips provided.

**SPECIES**

Lagomorph

Thank you for this referral. If the clinical or image interpretation does not parallel your findings or if I can be of any further assistance please contact me.

**BREED**

Dwarf

**Nele Eley**, DVM, Dr. med. vet., DipECVDI  
European Specialist in Veterinary Diagnostic Imaging, Cert. Radiology,  
Senior lecturer University of Giessen, Germany, Veterinary Faculty, Department of Radiology  
[info@sonopath.com](mailto:info@sonopath.com)

**SEX**

MN

**AGE**

6 Years

**INTERPRETED BY**

Nele Eley, DVM  
Dr. med. Vet. DipECVDI

**HOSPITAL NAME**

Bridgwater  
Veterinary Hospital  
and Wellness Centre

**REFERRING VET**

Dr. Mooi

**INVOICE**

59890

**DATE**

8-23-23