



PATIENT

Roxie Leu

PRESENTING CLINICAL SIGNS

monitoring process for suspect soft tissue sarcoma of the left shoulder

SPECIES

Canine

RADIOGRAPHIC STUDY OF THE THORAX

Right/left lateral and ventrodorsal views of the thorax totaling 3 images available for review and compared to prior study dated 10-25-21.

BREED

Boxer

RADIOGRAPHIC FINDINGS

The patient has a history of a soft tissue mass within the left axillary region known to be a soft tissue sarcoma.

SEX

FS

The soft tissue mass within the left axillary region appears to have grown in size which, however, may at least in part be due to different positioning.

AGE

10 Years, 3 Months

Multiple moderate spondyloses are seen within the mid and caudal thoracic spine.

Course and width of the trachea are considered within normal limits.

Mild upper esophageal aerophagia is noted.

There is no evidence of abnormal mediastinal widening.

INTERPRETED BY

Nele Eley, DVM
Dr. med. Vet. DipECVDI

There is no evidence of sternal lymphadenomegaly in the present study.

The cardiac silhouette presents within normal limits.

There is no evidence of pulmonary nodules or masses. Multiple age related pulmonary osteomas are seen.

HOSPITAL NAME

Gentle Doctor Animal
Hospital

RADIOGRAPHIC DIAGNOSIS

- No evidence of pulmonary nodules or masses.
- Soft tissue mass in the left axillary region with no evidence of intrathoracic extension.
- No evidence of sternal lymphadenomegaly.

REFERRING VET

Pete Bashara

INTERPRETATION OF THE FINDINGS & FURTHER RECOMMENDATIONS

The recent radiographic study reveals no evidence of pulmonary metastases. The mediastinal lymph nodes present within normal limits. There is no evidence of sternal lymphadenomegaly and the suspicion of intrathoracic extension of the left axillary mass is not confirmed. Progressive growth of the mass is suspected, however, this is subject to significant bias by different positioning comparing the various radiographic studies.

INVOICE

53651

DATE

8-23-22



PATIENT

Roxie Leu

SPECIES

Canine

BREED

Boxer

SEX

FS

AGE

10 Years, 3 Months

INTERPRETED BY

Nele Eley, DVM
Dr. med. Vet. DipECVDI

HOSPITAL NAME

Gentle Doctor Animal
Hospital

REFERRING VET

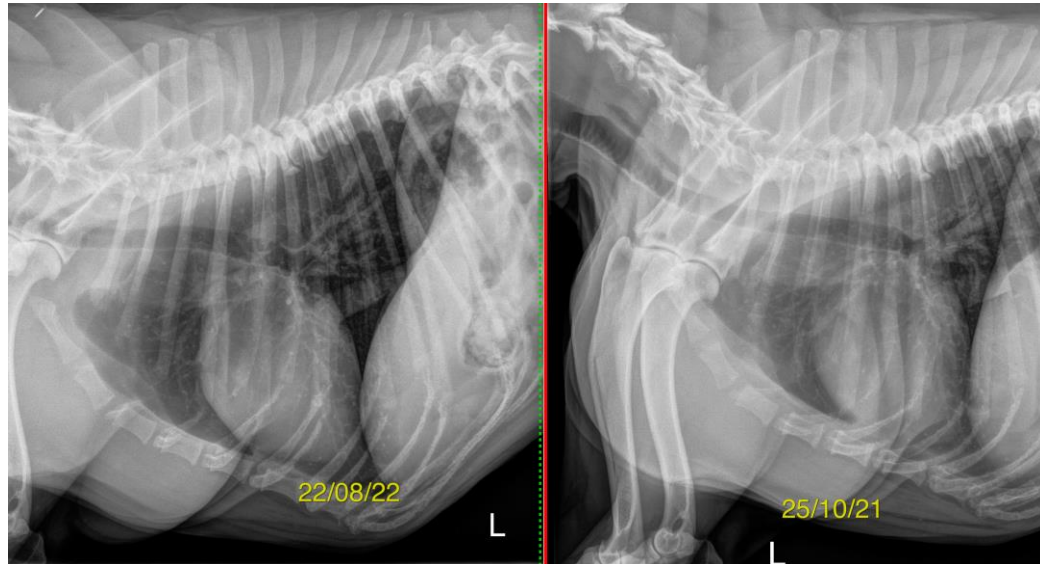
Pete Bashara

INVOICE

53651

DATE

8-23-22



The information and recommendations provided are based on the images presented by the referring veterinarian/sonographer. No evaluation can be communicated regarding pathology that was not visible in the image/video clips provided.

Thank you for this referral. If the clinical or image interpretation does not parallel your findings or if I can be of any further assistance please contact me.

Nele Eley, DVM, Dr. med. vet., DipECVDI
European Specialist in Veterinary Diagnostic Imaging, Cert. Radiology,
Senior lecturer University of Giessen, Germany, Veterinary Faculty, Department of Radiology
Nele.Eley@sonopath.com