



PATIENT

Lucy Stephens

PRESENTING CLINICAL SIGNS

~1 month hx of head tilt, torticollis and rotary nystagmus of varying severity. Presented to ER on 8-21-22 for head tilt, twitching and hyperesthesia. No torticollis or nystagmus at that time.

SPECIES

Canine

COMPUTED TOMOGRAPHIC STUDY OF THE HEAD

Plain and post contrast studies in soft tissue and bone windows available for review.

BREED

Beagle Mix

COMPUTED TOMOGRAPHIC FINDINGS

The tympanic bullae, osseous structures of the inner ear, and external auditory meatuses present within normal limits.

SEX

FS

A 10 x 12mm sized ovoid well delineated extraaxial intercranial mass is seen in the suprasellar region. There is a significant mass effect onto the thalamus and hypothalamus. The mass presents moderate uniform contrast enhancement.

Mild dilation of the lateral and third ventricles of the brain is noted.

AGE

10 Years

Multifocal severe periodontal disease is noted.

The submandibular and medial retropharyngeal lymph nodes present within normal limits.

INTERPRETED BY

Nele Eley, DVM
Dr. med. Vet. DipECVDI

COMPUTED TOMOGRAPHIC DIAGNOSIS

- Extraaxial suprasellar intercranial mass meeting neoplastic criteria.
- Mild ventriculomegaly.
- Severe periodontal disease with atrophy of the alveolar crest in all quadrants.

HOSPITAL NAME

Bluegrass Veterinary
Specialists

INTERPRETATION OF THE FINDINGS & FURTHER RECOMMENDATIONS

The CT study reveals a suprasellar extraaxial intercranial mass. Pituitary adenoma is a primary differential diagnosis. Meningioma and round cell neoplasia cannot be ruled out as differential diagnoses theoretically but are thought less likely.

REFERRING VET

Gover

The ventriculomegaly and intercranial mass effect are likely to be concurred by increased intercranial pressure.

INVOICE

53672

DATE

8-23-22



PATIENT

Lucy Stephens

SPECIES

Canine

BREED

Beagle Mix

SEX

FS

AGE

10 Years

INTERPRETED BY

Nele Eley, DVM
Dr. med. Vet. DipECVDI

HOSPITAL NAME

Bluegrass Veterinary
Specialists

REFERRING VET

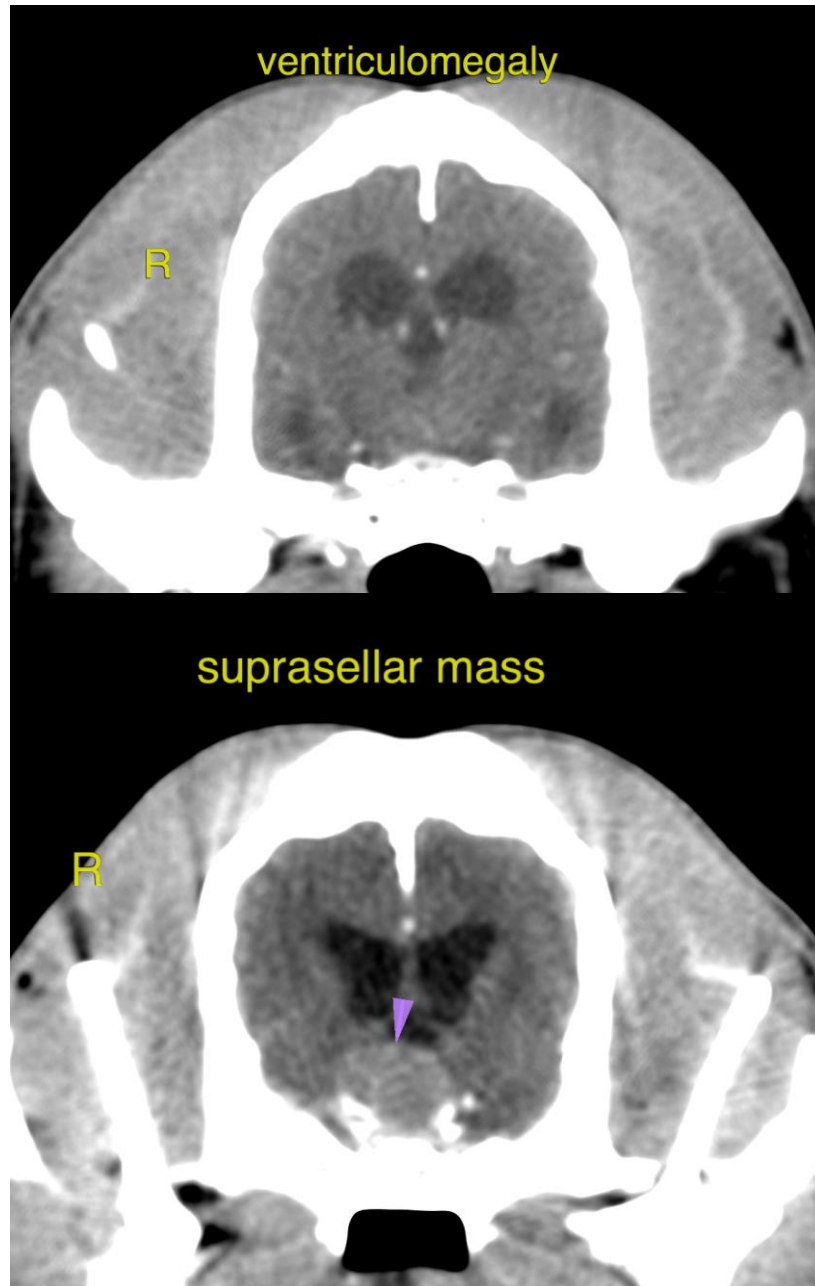
Gover

INVOICE

53672

DATE

8-23-22





PATIENT

Lucy Stephens

The information and recommendations provided are based on the images presented by the referring veterinarian/sonographer. No evaluation can be communicated regarding pathology that was not visible in the image/video clips provided.

Thank you for this referral. If the clinical or image interpretation does not parallel your findings or if I can be of any further assistance please contact me.

SPECIES

Canine

Nele Eley, DVM, Dr. med. vet., DipECVDI
European Specialist in Veterinary Diagnostic Imaging, Cert. Radiology,
Senior lecturer University of Giessen, Germany, Veterinary Faculty, Department of Radiology
Nele.Eley@sonopath.com

BREED

Beagle Mix

SEX

FS

AGE

10 Years

INTERPRETED BY

Nele Eley, DVM
Dr. med. Vet. DipECVDI

HOSPITAL NAME

Bluegrass Veterinary
Specialists

REFERRING VET

Gover

INVOICE

53672

DATE

8-23-22