



**PATIENT**

Kitty Ponichtera

**PRESENTING CLINICAL SIGNS**

Chronic nasal discharge, sneezing, and coughing

**SPECIES**

Feline

**COMPUTED TOMOGRAPHIC STUDY OF THE HEAD**

Plain and post contrast studies available for review.

**BREED**

DSH

**COMPUTED TOMOGRAPHIC FINDINGS**

A moderate amount of fluid attenuating material is seen between the nasal turbinates in both nasal cavities. The left frontal sinus contains a moderate amount of fluid attenuating material. There is multifocal mucosal swelling within both nasal cavities. Mild bilateral turbinate destruction is seen. There is no evidence of aggressive osteolytic lesions, a soft tissue mass, or foreign material. The cribriform plate is intact. No evidence of nasopharyngeal stenosis is noted.

**SEX**

Female

The left tympanic bulla presents moderate swelling of its mucosal lining.

The regional lymph nodes present within normal limits.

**AGE**

9 Years

**COMPUTED TOMOGRAPHIC DIAGNOSIS**

- Mildly erosive rhinosinusitis.
- Mild left sided otitis media

**INTERPRETED BY**

Nele Eley, DVM  
Dr. med. Vet. DipECVDI

**INTERPRETATION OF THE FINDINGS & FURTHER RECOMMENDATIONS**

The CT study reveals chronic and mildly erosive bilateral rhinosinusitis as well as left sided otitis media. Infectious rhinosinusitis and otitis such as bacterial are thought most likely. Bacterial, viral, and mixed infection of the nasal cavities and paranasal sinuses is one primary differential diagnosis. Lymphoplasmacytic rhinitis cannot be ruled out entirely as a differential diagnosis and further definition by means of rhinoscopy with sampling should be considered if not performed already.

**HOSPITAL NAME**

Scottsdale Veterinary  
Clinic

**REFERRING VET**

Dr. Tanaka

**INVOICE**

53677

**DATE**

8-23-22



**PATIENT**

Kitty Ponichtera

**SPECIES**

Feline

**BREED**

DSH

**SEX**

Female

**AGE**

9 Years

**INTERPRETED BY**

Nele Eley, DVM  
Dr. med. Vet. DipECVDI

**HOSPITAL NAME**

Scottsdale Veterinary  
Clinic

**REFERRING VET**

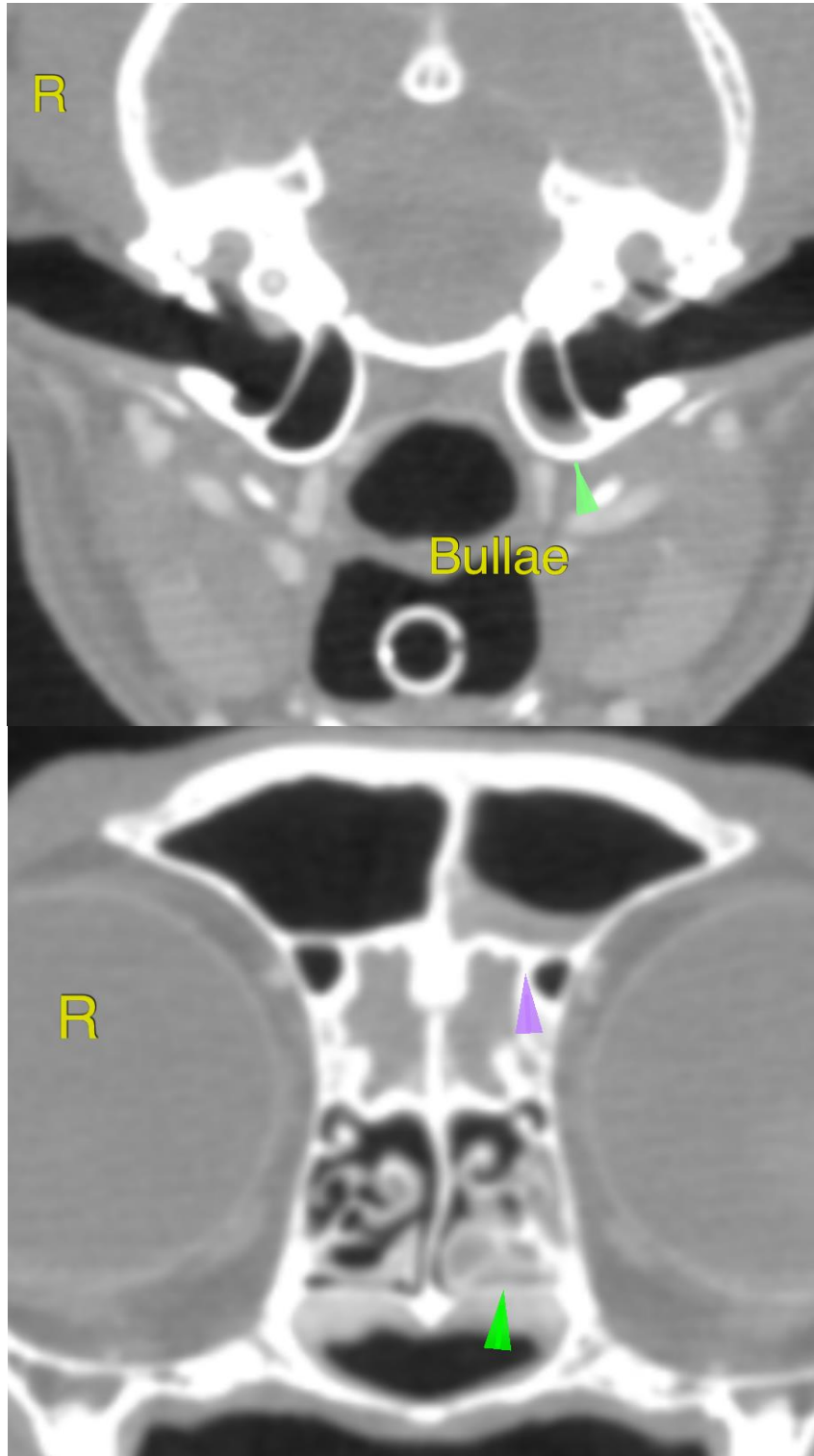
Dr. Tanaka

**INVOICE**

53677

**DATE**

8-23-22





**PATIENT**

Kitty Ponichtera

The information and recommendations provided are based on the images presented by the referring veterinarian/sonographer. No evaluation can be communicated regarding pathology that was not visible in the image/video clips provided.

**SPECIES**

Feline

Thank you for this referral. If the clinical or image interpretation does not parallel your findings or if I can be of any further assistance please contact me.

**BREED**

DSH

**Nele Eley**, DVM, Dr. med. vet., DipECVDI  
European Specialist in Veterinary Diagnostic Imaging, Cert. Radiology,  
Senior lecturer University of Giessen, Germany, Veterinary Faculty, Department of Radiology  
Nele.Eley@sonopath.com

**SEX**

Female

**AGE**

9 Years

**INTERPRETED BY**

Nele Eley, DVM  
Dr. med. Vet. DipECVDI

**HOSPITAL NAME**

Scottsdale Veterinary  
Clinic

**REFERRING VET**

Dr. Tanaka

**INVOICE**

53677

**DATE**

8-23-22