



PATIENT

MAKI LEWIS

PRESENTING CLINICAL SIGNS

O STATES BREATHING IS WORSE. ALSO, MORE PANTING AND SNORING. History: BREATHING GOT WORSE AFTER ANTIBIOTICSS WERE FINISHED. ALSO IS MAKING VOMITING SOUNDS THEN BURPS.

SPECIES

Feline

Abnormal PE/Chem/CBC/UA Results: Mentation: BAR EENT: No nasal discharge; clear no discharge OU; clean no exudate AU; No cough on tracheal palpation. Oral Cavity: Normal deciduous teeth, erupting permanent teeth, fractured maxillary deciduous canine Skin: Good hair coat, no signs of ectoparasites. No lesions noted. CV/Respiratory: No murmur/arrhythmia or crackles/wheezing auscultated. Synchronous pulses, normal rate. Normal bronchovesicular sounds.

BREED

German Shepherd
Dog

RADIOGRAPHIC STUDY OF THE THORAX

Right lateral and ventrodorsal views totaling 2 images available for review. Compared to prior study dated 8-9-21.

SEX

Female Intact

RADIOGRAPHIC FINDINGS

The degree of pulmonary inflation is moderate. A mild increase in bronchointerstitial opacity is seen compared to the prior study.

AGE

18 Weeks

The cardiac silhouette is upright and thin. The pulmonary vasculature is thin.

Mild esophageal aerophagia is noted.

INTERPRETED BY

Nele Eley, DVM
Dr. med. Vet. DipECVDF

A thymic remnant is seen and considered within age related normal limits.

RADIOGRAPHIC DIAGNOSIS

- Mildly progressive generalized bronchointerstitial lung pattern.
- Hypovolemia with microcardia and underperfusion of the lung.

HOSPITAL NAME

DPC Veterinary
Hospital

INTERPRETATION OF THE FINDINGS & FURTHER RECOMMENDATIONS

The radiographic study shows mild progression of a bronchointerstitial lung pattern. With the patient's history, infectious bronchitis / tracheobronchitis, based on a mixed viral and/or bacterial infection, is thought most likely. Noninfectious allergic bronchopneumopathy or other cannot be ruled out entirely but is thought by far less likely. The findings are neither typical for parasitic bronchitis even though airway sampling would be necessary for a final diagnosis.

REFERRING VET

Dr. Duke

INVOICE

47103

DATE

8-23-21



PATIENT

MAKI LEWIS

SPECIES

Feline

BREED

German Shepherd
Dog

SEX

Female Intact

AGE

18 Weeks

INTERPRETED BY

Nele Eley, DVM
Dr. med. Vet. DipECVDI

HOSPITAL NAME

DPC Veterinary
Hospital

REFERRING VET

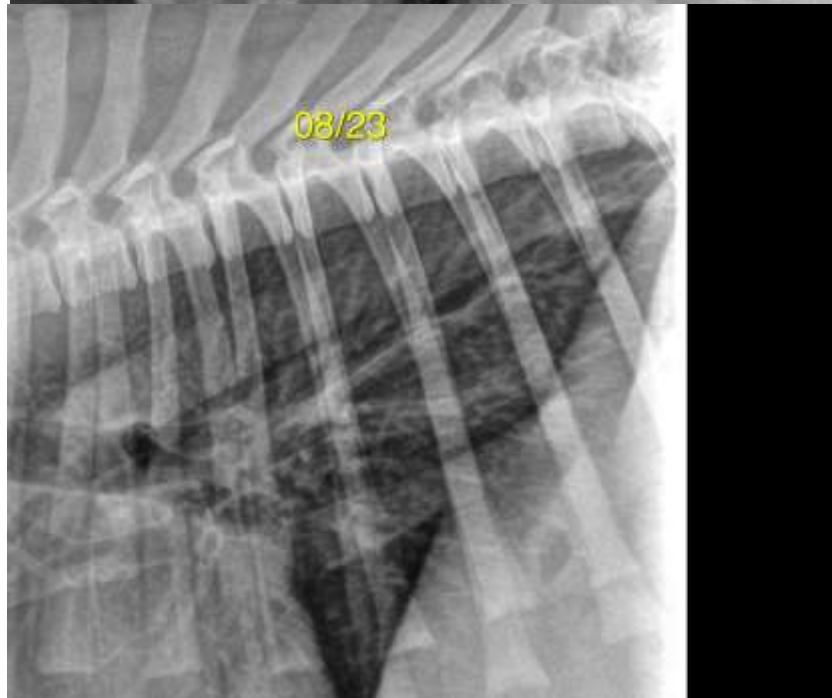
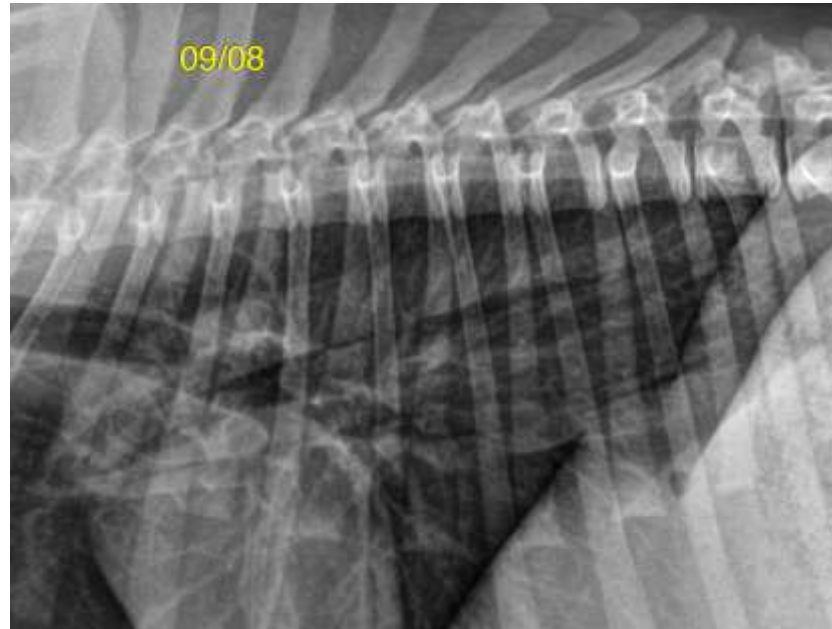
Dr. Duke

INVOICE

47103

DATE

8-23-21





PATIENT

MAKI LEWIS

The information and recommendations provided are based on the images presented by the referring veterinarian. No evaluation can be communicated regarding pathology that was not visible in the image/video clips provided.

Thank you for this referral. If the clinical or image interpretation does not parallel your findings or if I can be of any further assistance please contact me.

SPECIES

Feline

Nele Eley, DVM, Dr. med. vet., DipECVDI
European Specialist in Veterinary Diagnostic Imaging, Cert. Radiology,
Senior lecturer University of Giessen, Germany, Veterinary Faculty, Department of Radiology
Nele.Eley@sonopath.com

BREED

German Shepherd
Dog

SEX

Female Intact

AGE

18 Weeks

INTERPRETED BY

Nele Eley, DVM
Dr. med. Vet. DipECVDI

HOSPITAL NAME

DPC Veterinary
Hospital

REFERRING VET

Dr. Duke

INVOICE

47103

DATE

8-23-21