



PATIENT

Pluto Awashti

PRESENTING CLINICAL SIGNS

right elbow pain on flexion appreciable swelling
Abnormal PE/Chem/CBC/UA Results: not performed

SPECIES

Canine

COMPUTED TOMOGRAPHIC STUDY OF THE THORACIC LIMBS

Shoulders to the Carpi - Plain studies in soft tissue and bone windows are available for review.

BREED

Golden Retriever

COMPUTED TOMOGRAPHIC FINDINGS

Right Elbow

Moderate smooth new bone formation is seen at the medial humeral condyle, medial humeral epicondyle, and medial contour of the right proximal ulna.

SEX

MN

There is no evidence of fragmentation of the medial coronoid process, osteochondritis, or significant joint incongruity.

AGE

3

Moderate soft tissue swelling is seen medial and caudal to the left elbow joint in the region of the flexor origin. A post-contrast study is not available.

Left Elbow

The left elbow presents minimal periarticular osteophytes.

INTERPRETED BY

Nele Eley, DVM
Dr. med. Vet. DipECVDI

The medial coronoid process and humeral condyles present within expected limits.

Shoulders & Carpi

The bilateral shoulders and carpal joints present within age related normal limits.

HOSPITAL NAME

Advanced Veterinary
Imaging

COMPUTED TOMOGRAPHIC DIAGNOSIS

- Right elbow arthropathy with periarticular soft tissue swelling and new bone formation in the medial compartment.
- Early degenerative joint disease of the left elbow.
- Normal shoulders and carpi.

REFERRING VET

Eamon

INTERPRETATION OF THE FINDINGS & FURTHER RECOMMENDATIONS

Chronic flexor enthesopathy is a primary differential diagnosis. However, owing to the lack of a post-contrast study, soft tissue mass such as hematoma, neoplasia, as well as muscular avulsion cannot be ruled out as potential differential diagnoses.

INVOICE

59859

DATE

8-22-23



PATIENT

Pluto Awashti

SPECIES

Canine

BREED

Golden Retriever

SEX

MN

AGE

3

INTERPRETED BY

Nele Eley, DVM
Dr. med. Vet. DipECVDI

HOSPITAL NAME

Advanced Veterinary
Imaging

REFERRING VET

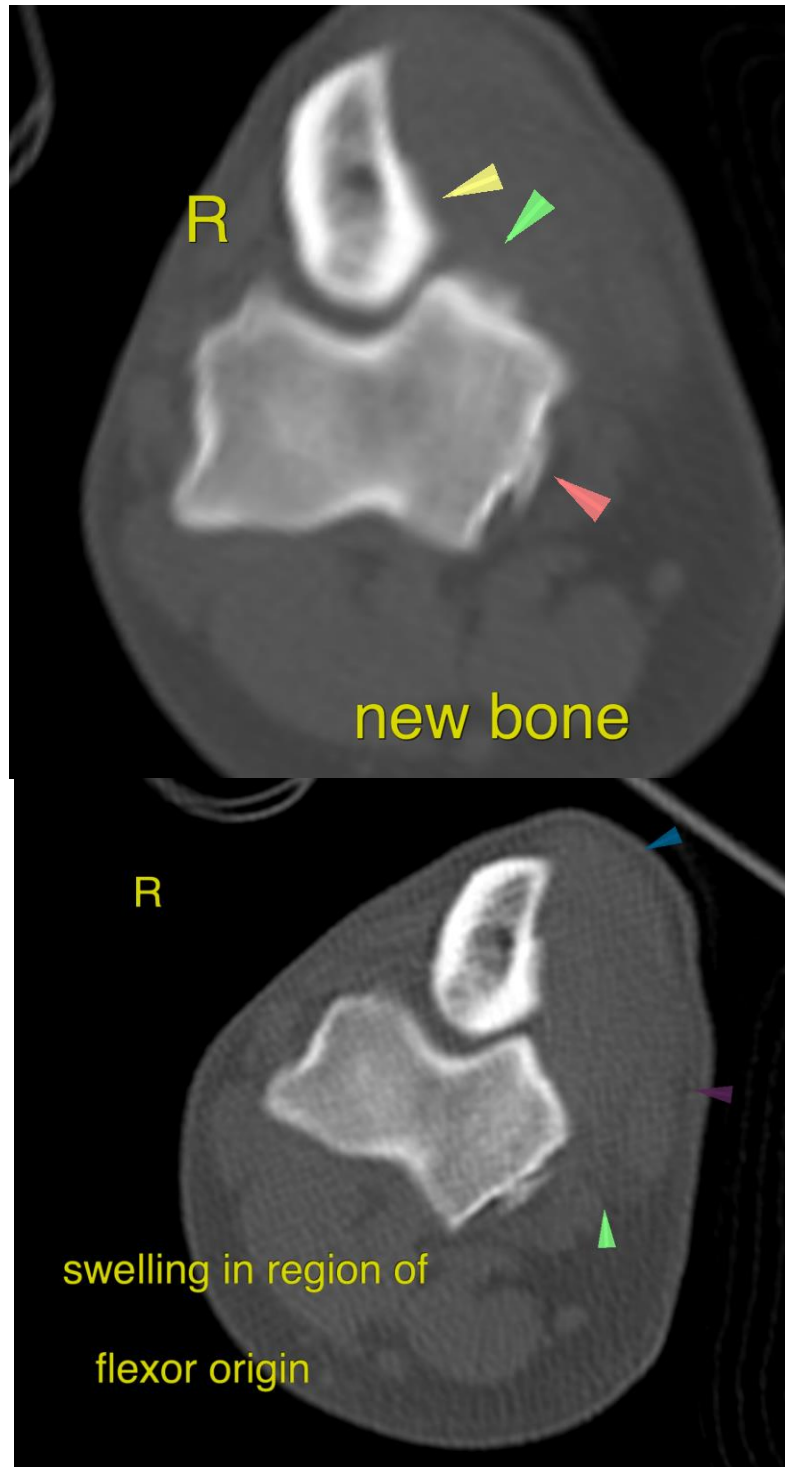
Eamon

INVOICE

59859

DATE

8-22-23





PATIENT

Pluto Awashti

The information and recommendations provided are based on the images presented by the referring veterinarian/sonographer. No evaluation can be communicated regarding pathology that was not visible in the image/video clips provided.

SPECIES

Canine

Thank you for this referral. If the clinical or image interpretation does not parallel your findings or if I can be of any further assistance please contact me.

BREED

Golden Retriever

Nele Eley, DVM, Dr. med. vet., DipECVDI
European Specialist in Veterinary Diagnostic Imaging, Cert. Radiology,
Senior lecturer University of Giessen, Germany, Veterinary Faculty, Department of Radiology
info@sonopath.com

SEX

MN

AGE

3

INTERPRETED BY

Nele Eley, DVM
Dr. med. Vet. DipECVDI

HOSPITAL NAME

Advanced Veterinary
Imaging

REFERRING VET

Eamon

INVOICE

59859

DATE

8-22-23