

**PATIENT**

Sophie Jule

PRESENTING CLINICAL SIGNS

History of anal gland adenocarcinoma and mammary adenocarcinoma. one year post surgery. cardiomegaly, with no metastasis.
Abnormal PE/Chem/CBC/UA Results: cbc chem

SPECIES

Canine

RADIOGRAPHIC STUDY OF THE THORAX

The surrounding bony structures are within normal limits.

BREED

Golden Retriever

The extrathoracic soft tissues present homogeneous without abnormalities.

Mild generalized enlargement of the cardiac silhouette is noted with no evidence of a concurrent vascular lung pattern. The vertebral heart score is 10.6. The pulmonary vasculature is within normal limits.

SEX

Female Spayed

The cranial mediastinum presents the expected soft tissue opacity. The mediastinal width is less than twice the width of the vertebral column at the same level.

The trachea is normal in diameter and presents the anticipated course. The luminal outline of the trachea is smooth.

AGE

11 Years

The lung presents a mild generalized bronchointerstitial pattern. No evidence of pulmonary nodules or masses is seen.

INTERPRETED BY

Nele Eley, DVM
Dr. med. Vet. DipECVDI

The diaphragm is well delineated with even surface and the expected mild cranial bulging of the diaphragmatic cupola.

RADIOGRAPHIC DIAGNOSIS

- Mild generalized cardiomegaly
- No evidence of pulmonary metastatic disease.

HOSPITAL NAME

Northshore
Veterinary Hospital

INTERPRETATION OF THE FINDINGS & FURTHER RECOMMENDATIONS

The radiographic study reveals mild generalized cardiomegaly with borderline enlargement of the cardiac silhouette at a vertebral heart score of 10.6 which is not necessarily associated with volume overload. Differential diagnosis includes diastolic exposure, anemia, bradycardia, fever as well as mild true cardiac enlargement. At this time, there is no radiographic evidence of congestive heart failure; neither did the radiographic study reveal evidence of pulmonary metastatic disease.

REFERRING VET

Kimberly Barron

INVOICE

53634

DATE

8-22-22



PATIENT

Sophie Jule

SPECIES

Canine

BREED

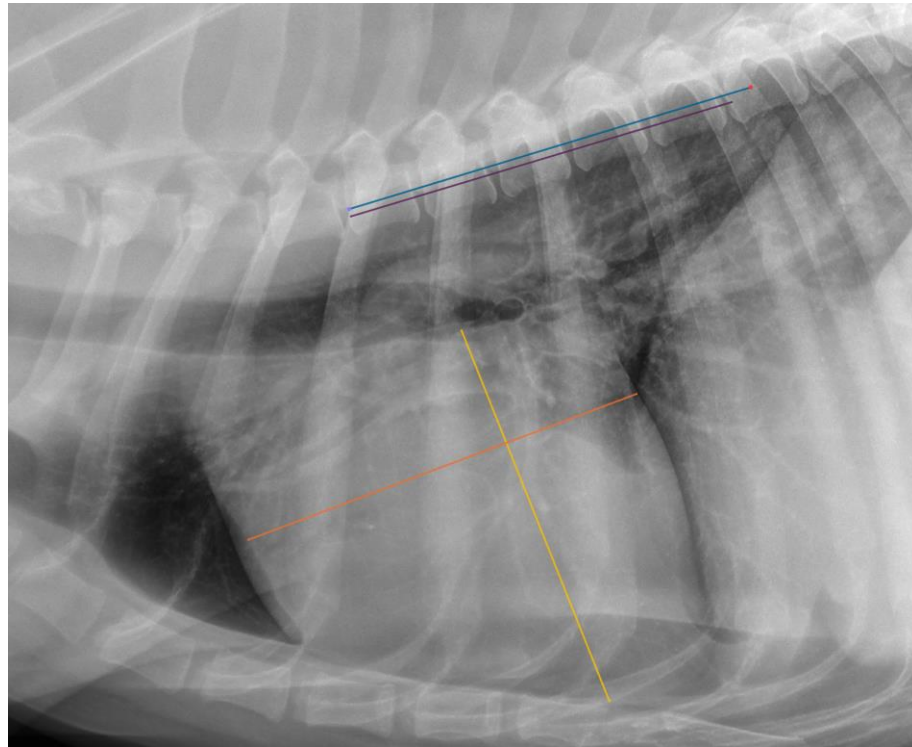
Golden Retriever

SEX

Female Spayed

AGE

11 Years



INTERPRETED BY

Nele Eley, DVM
Dr. med. Vet. DipECVDI

The information and recommendations provided are based on the images presented by the referring veterinarian/sonographer. No evaluation can be communicated regarding pathology that was not visible in the image/video clips provided.

HOSPITAL NAME

Northshore
Veterinary Hospital

Thank you for this referral. If the clinical or image interpretation does not parallel your findings or if I can be of any further assistance please contact me.

Nele Eley, DVM, Dr. med. vet., DipECVDI
European Specialist in Veterinary Diagnostic Imaging, Cert. Radiology,
Senior lecturer University of Giessen, Germany, Veterinary Faculty, Department of Radiology
Nele.Eley@sonopath.com

REFERRING VET

Kimberly Barron

INVOICE

53634

DATE

8-22-22